Syndromes interstitiels

TUSAR région Ouest

Tours, 08 décembre 2023

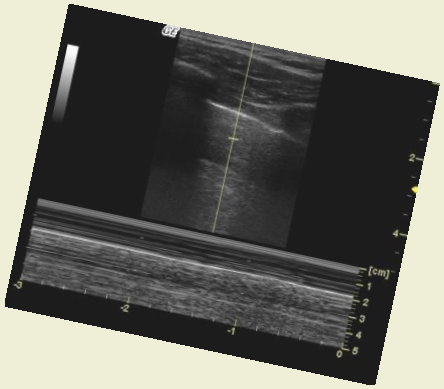

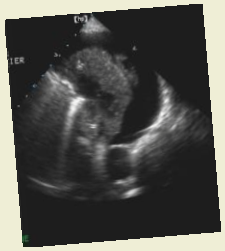

Pr F. Remérand
Anesthésie-Réanimation 2
C.H.R.U. de Tours, hôpital Trousseau
francis.remerand@univ-tours.fr

Pas de conflit d'intérêt.

Recommandations et échographie pleuropulmonaire

Intensive Care Med (2012) 38:577–591
DOI 10.1007/s00134-012-2513-4

CONFERENCE REPORTS AND EXPERT PANEL

2012

Giovanni Volpicelli
Mahmoud Elbarbary
Michael Blaivas
Daniel A. Lichtenstein
Gebhard Mathis
Andrew W. Kirkpatrick

International evidence-based recommendations for point-of-care lung ultrasound

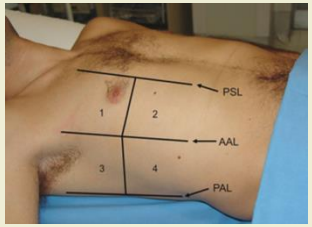

RP < écho = TDM

European Heart Journal (2016) **37**, 2129–2200
doi:10.1093/eurheartj/ehw128

Clinique bio RP **<u>et écho</u>**

2016 ESC Guidelines for the diagnosis and treatment of acute and chronic heart failure

The Task Force for the diagnosis and treatment of acute and chronic heart failure of the European Society of Cardiology (ESC)

Plan

Sémiologie <u>qualitative</u>

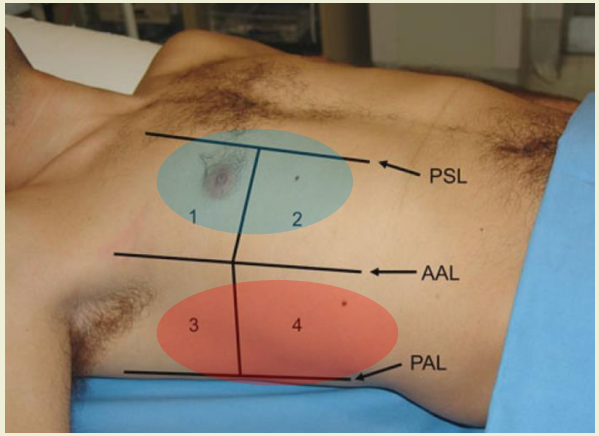

Sémiologie <u>quantitative</u>

Sémiologie <u>qualitative</u> :

- Pneumothorax
- Syndrome interstitiel

= analyse des artefacts

- Condensation pulmonaire
- Épanchement liquidien

= imagerie « anatomique »

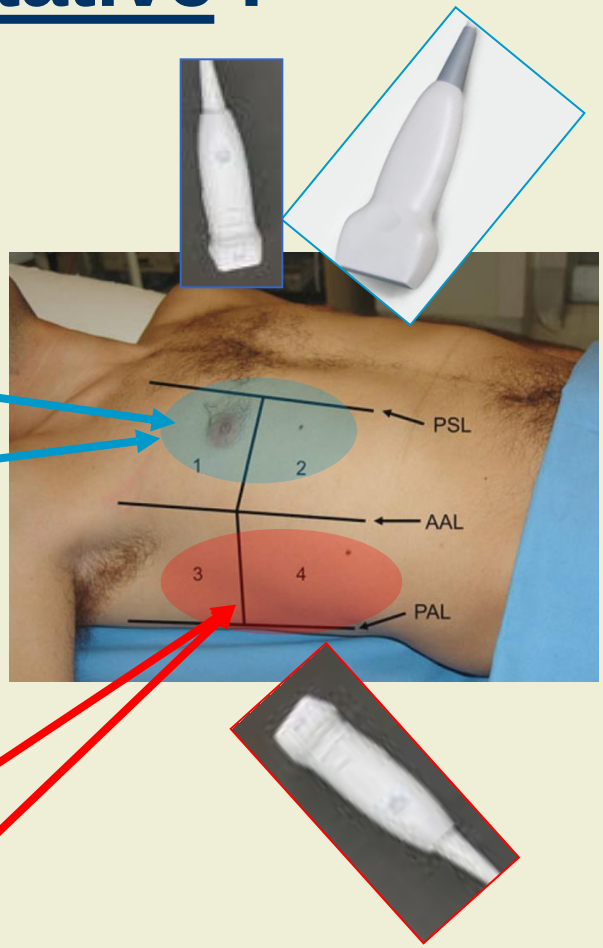

Historique

- Première description artefact en queue de comète… intrahépatique !

J Ultrasound Med. 1982 Jan-Feb;1(1):1-7.

The comet tail artifact.

Ziskin MC[1], Thickman DI, Goldenberg NJ, Lapayowker MS, Becker JM.

- Description du syndrome alvéolo-interstitiel échographique

Am J Respir Crit Care Med. 1997 Nov;156(5):1640-6.

The comet-tail artifact. An ultrasound sign of alveolar-interstitial syndrome.

Lichtenstein D[1], Mézière G, Biderman P, Gepner A, Barré O.

Historique

« Queues de Comètes »

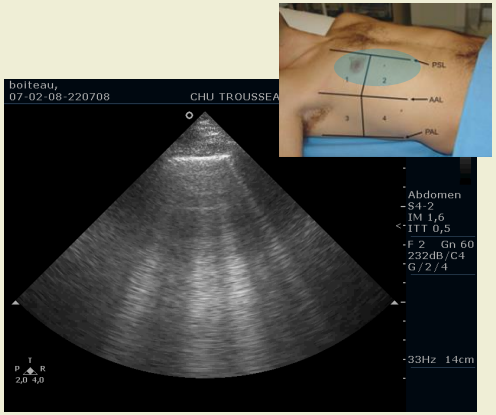

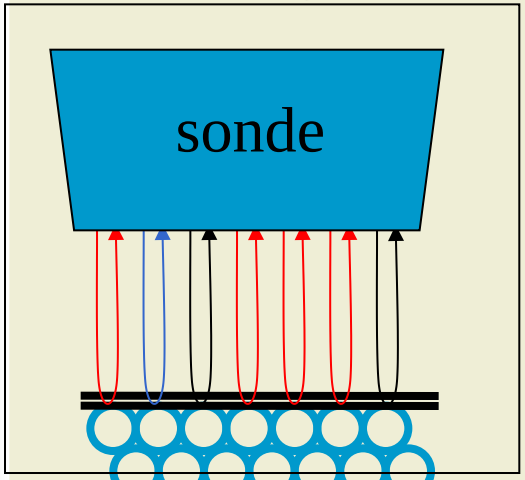

Formation de l'image :

Septas visibles (7 mm…) ?

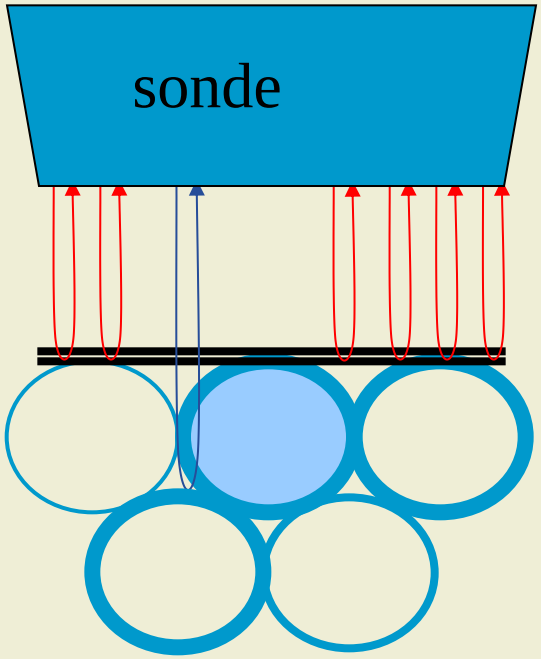



Actuellement :

« Queues de Comètes » = « lignes B »

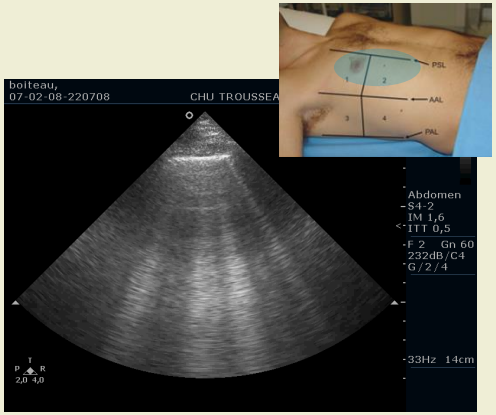

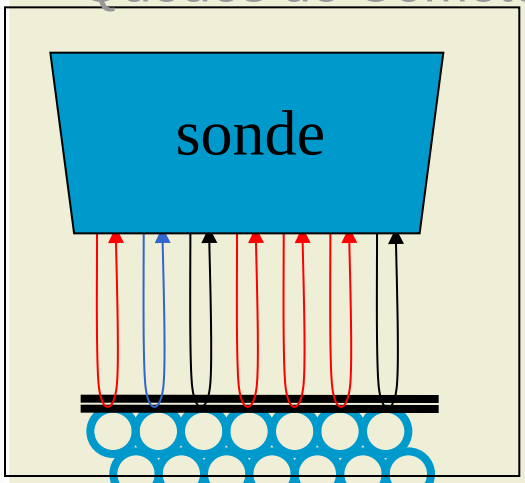

Formation de l'image :

Artefact de réverbération

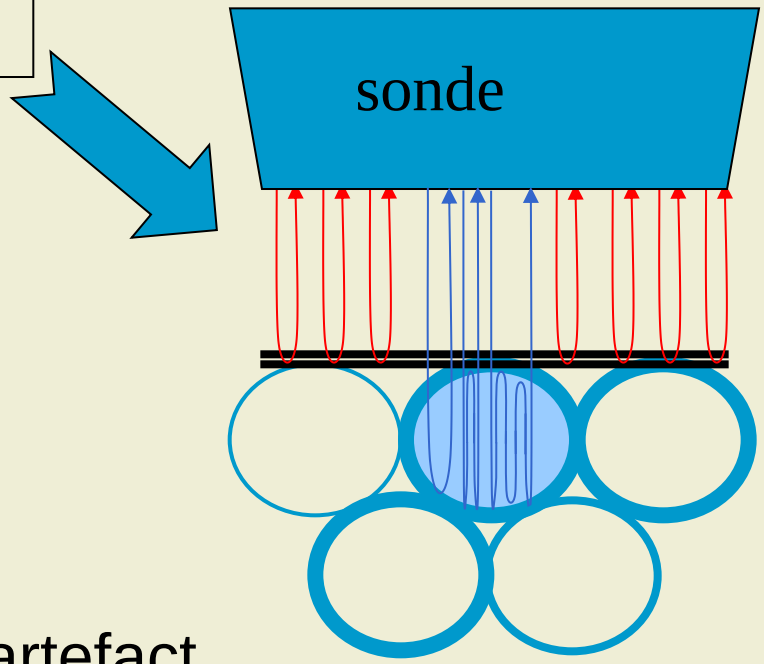



+/- Ring down artefact

Ligne B

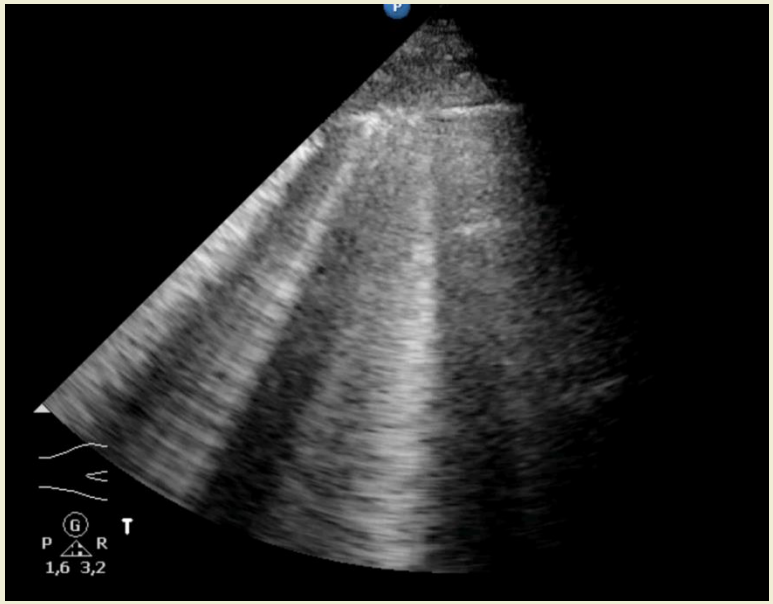

7 caractères :artefact

- nait de la plèvre
- vertical
- hyperéchogène
- bien défini
- traverse l’écran
- efface les lignes A
- suit le glissement pleural

À analyser seulement en anterieur (= en zone non déclive +++)

Ligne Z

- 7 caractères :
  - artefact vertical
  - Plus ou moins bien défini
  - hyperéchogène
  - naissant de la plèvre
  - Ne traverse pas l'écran
  - N'efface pas les lignes A
  - suit le glissement pleural

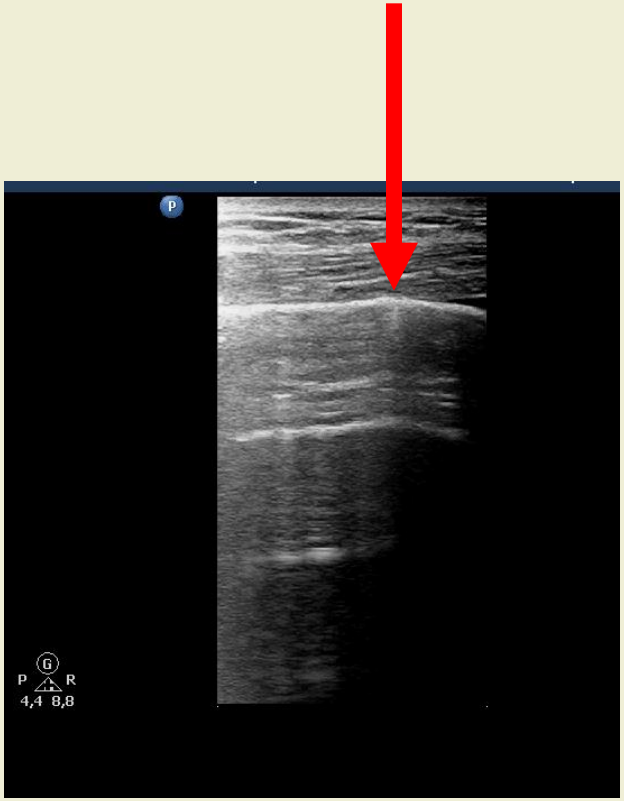

définition du sd interstitiel

(examen à 8 régions antérieures ou latérales)

- Au moins 3 lignes B par scan
- Au moins 2 scan du même coté
- Lignes B bilatérales

- Sensibilité 86%, spécificité 98%

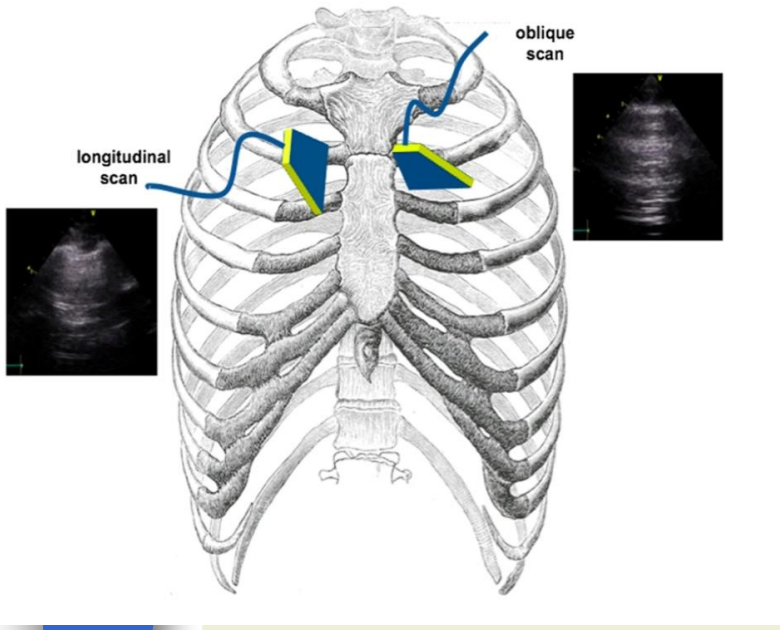

International evidence-based recommendations for point-of-care lung ultrasound

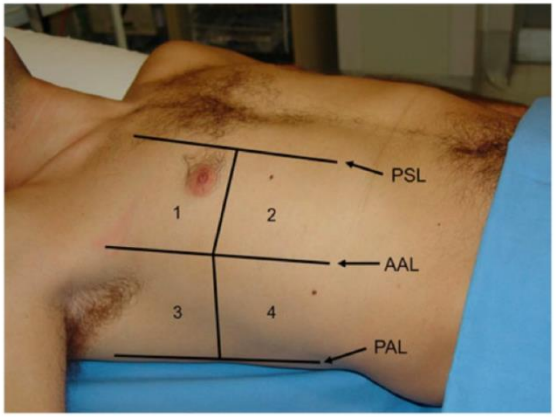

Volpicelli et al, ICM 2012

Sensibilité diagnostique

- Echo > RP dans le SDRA

Table 1. Sensitivity and Specificity of Auscultation, Chest Radiography, and Lung Ultrasonography for Diagnosing Pleural Effusion, Alveolar Consolidation, and Alveolar–Interstitial Syndrome in 384 Lung Regions in 32 Critically Ill Patients with ARDS

	Auscultation, %	Chest Radiography, %	Lung Ultrasonography, %
Pleural effusion			
Sensitivity	42	39	92
Specificity	90	85	93
Diagnostic accuracy	61	47	93
Alveolar consolidation			
Sensitivity	8	68	93
Specificity	100	95	100
Diagnostic accuracy	36	75	97
Alveolar–interstitial syndrome			
Sensitivity	34	60	98
Specificity	90	100	88
Diagnostic accuracy	55	72	95

ARDS = acute respiratory distress syndrome.

Lichtenstein et al, Anesthesiology 2004

Sensibilité/spécificité comparées au TDM en traumatologie

Contusion pulmonaire = sd interstitiel (pas condensation !!!)

Table 2 Sensitivity, specificity, positive and negative predictive values, and diagnostic accuracy of CXR and lung ultrasound (LU) compared to CT scan for each abnormality and for each hemithorax

Pathology	LU/CXR	CT +	CT −	Sensitivity (%)[a]	Specificity (%)[b]	PPV (%)[c]	NPV (%)[d]	DA (%)[e]
Consolidation	LU +	66	4	100	78	94	100	95
	LU −	0	14					
	CXR +	25	2	38	89	93	28	49
	CXR −	41	16					
Pneumothorax	LU +	6	5	75	93	55	97	92
	LU −	2	71					
	CXR +	0	1	0	99	0	90	89
	CXR −	8	75					
Pleural effusion	LU +	63	0	100	100	100	100	100
	LU −	0	21					
	CXR +	41	4	65	81	91	44	69
	CXR −	22	17					
Interstitial syndrome	LU +	51	2	94	93	96	90	94
	LU −	3	28					
	CXR +	25	6	46	80	81	45	58
	CXR −	29	24					

Each hemithorax was characterized as positive (+) or negative (−) for the abnormality by the presence or absence of a single positive region, respectively

TP true positive, *TN* true negative, *FP* false positive, *FN* false negative

[a] Sensitivity = [TP/(TP + FN)] × 100

[b] Specificity = [TN/(TN + FP)] × 100

[c] Positive predictive value (PPV) = [TP/(TP + FP)] × 100

[d] Negative predictive value (NPV) = [TN/(TN + FN)] × 100

[e] Diagnostic accuracy (DA) = [(TP + TN)/(TP + TN + FP + FN)] × 100

Xirouchaki et al, ICM 2011

Les syndromes interstitiels

Différencier OAP et SDRA / contusion +++

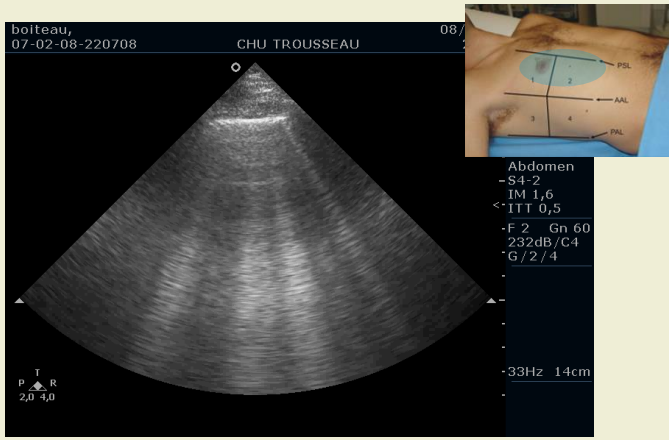

Œdème cardiogénique : >3 QDC fines, diffuses, antérieures

ALI ou SDRA ou contusion pulmonaire

= idem MAIS non fines, avec

- alternance de zones avec ou sans QDC
- des zones avec glissement pleural réduit ou nul
- aspect en motte de certaines QDC
- zones de condensation associées

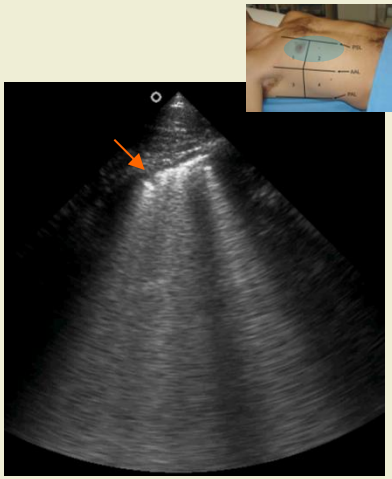

Copetti *Cardiovasc Ultrasound* 2008

Les syndromes interstitiels

Différencier OAP et SDRA et contusion… et fibrose ?

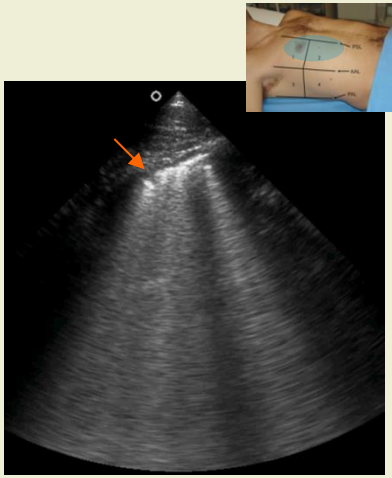

ALI ou SDRA ou contusion pulm

= idem MAIS non fines, avec

- alternance de zones avec ou sans QDC
- des zones avec glissement pleural réduit ou nul
- aspect en motte de certaines QDC
- zones de condensation associées

Copetti *Cardiovasc Ultrasound* 2008

Fibrose pulmonaire = QDC **postérieures** >> antérieures

- Avec épaississement pleural irrégulier > 3 mm
- Avec des zones avec glissement pleural réduit ou nul
- Avec aspect de kystes sous pleuraux
- Sans zone de condensation

!!!!!

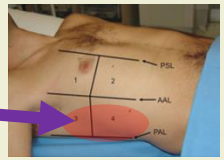

Sperandeo *Ultrasound Med Biol* 2009

Les syndromes interstitiels

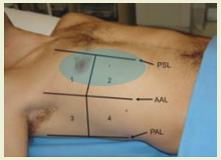

Différencier OAP et SDRA +++
En mode TM

N=14

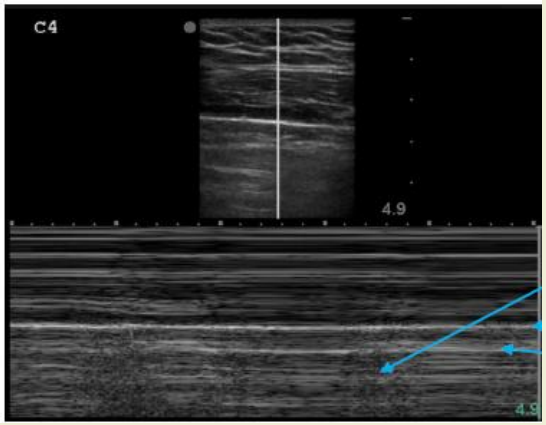

Normal :

ligne pleurale continue,

motifs sous pleuraux « horizontaux »

N=12

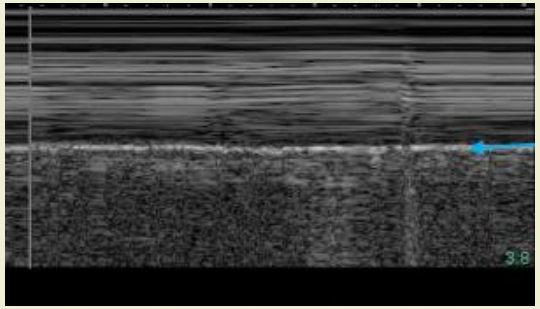

Œdème cardiogénique :

ligne pleurale continue,

motifs sous pleuraux « verticaux »

N=17

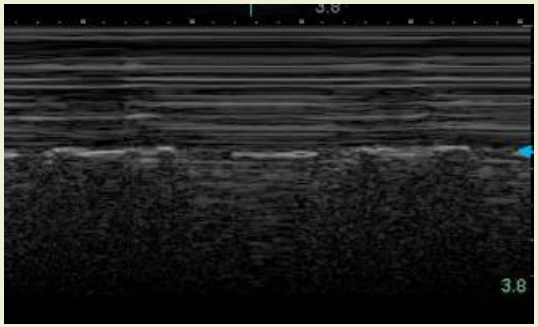

ALI ou SDRA =

ligne pleurale discontinue,

motifs sous pleuraux « verticaux »

Singh *Chest* 2017

- 3 pièges :

1- Pressions respiratoires : ZEEP vs PEEP 15

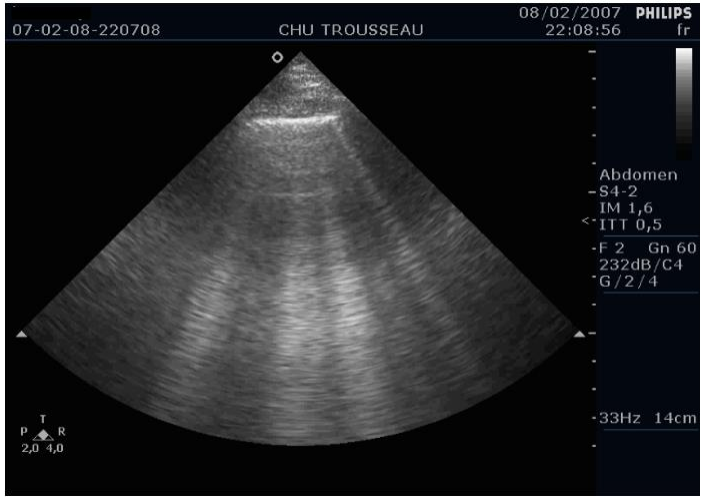

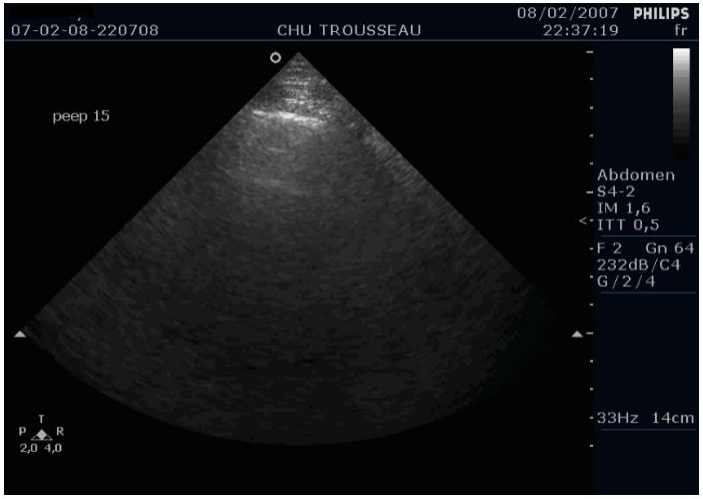

2- Lignes B post déclives = anodin !

3- Lignes Z…

Échographie pulmonaire: sémiologie quantitative

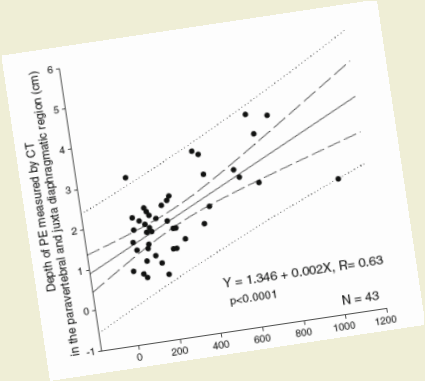

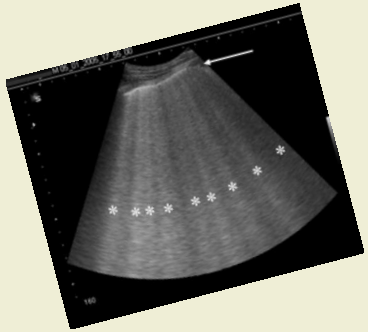

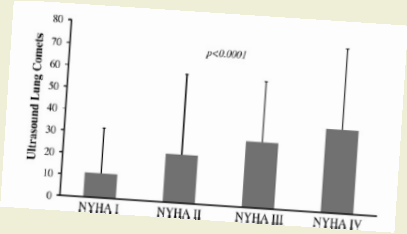

Syndromes interstitiels

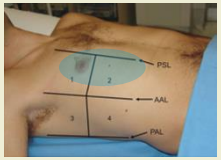

= comptage des lignes B = détection de la congestion pulmonaire infra clinique ?

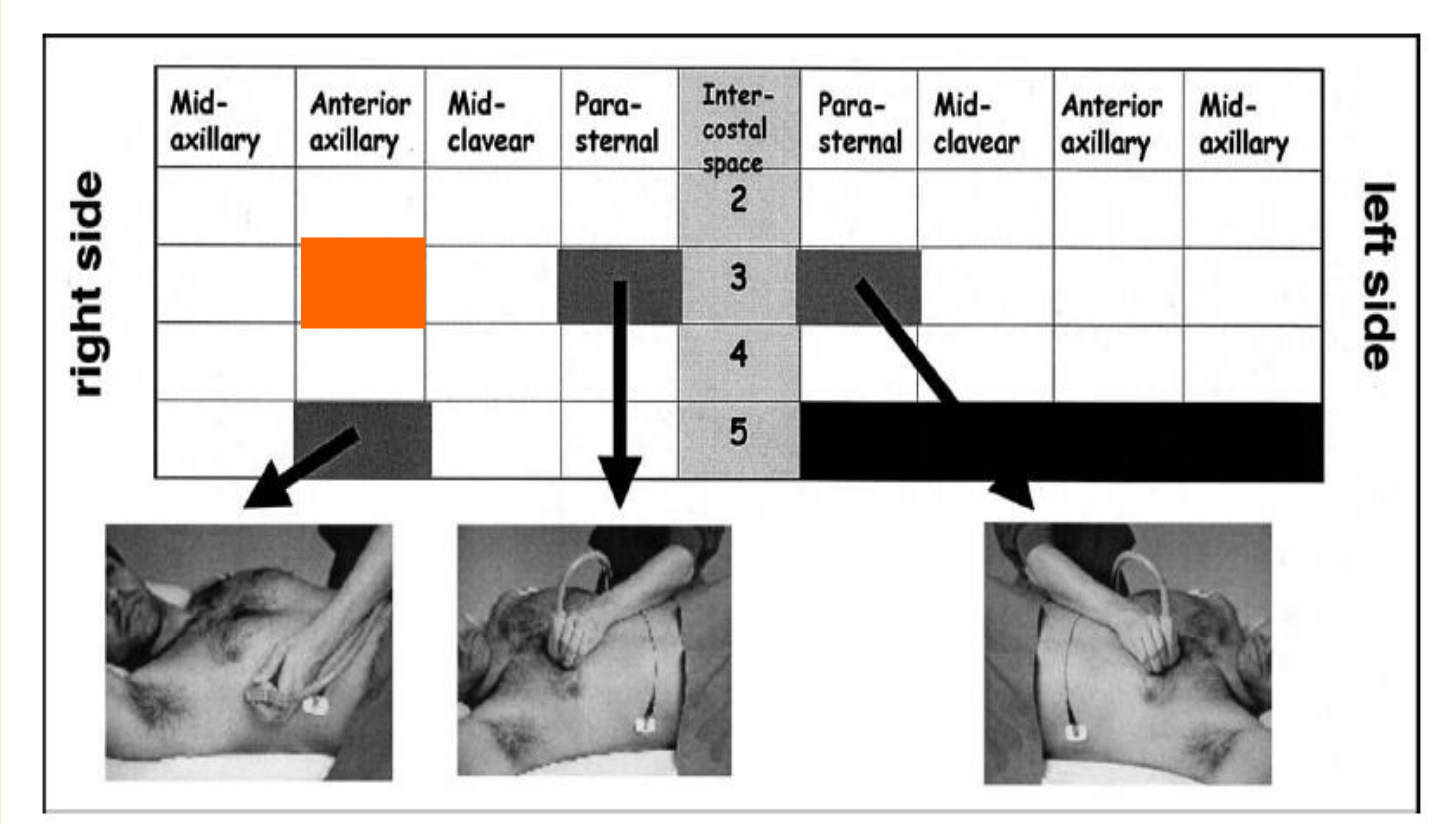

Bientôt un comptage des lignes B automatisé ?

Raso *JACC* 2015

Reproductibilité / Apprentissage

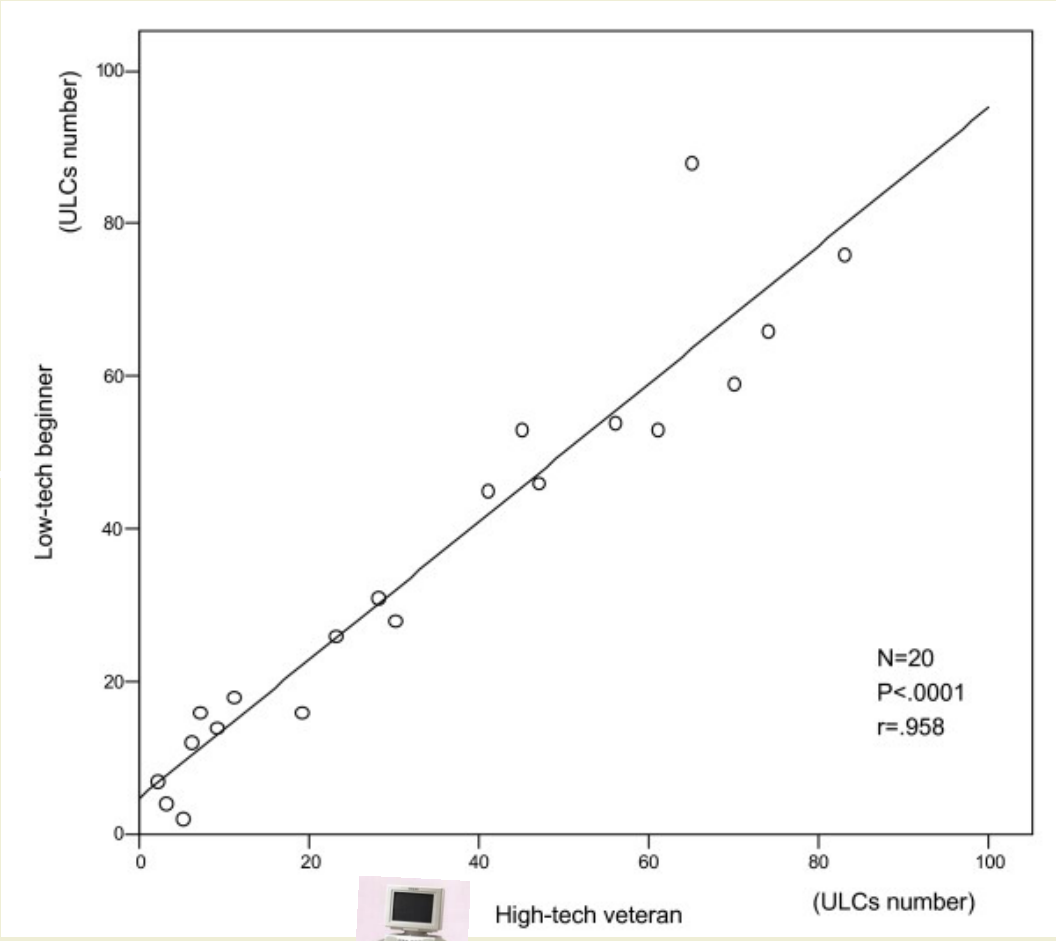

Bedetti et al, Cardiovasc ultrasound 2006

Aspect quantitatif : 28 quadrants

28 quadrants

right side	Mid-axillary	Anterior axillary	Mid-clavicular	Para-sternal	Inter-costal space	Para-sternal	Mid-clavicular	Anterior axillary	Mid-axillary	left side
					II					
					III					
					IV					
					V					

Jambrik Z, Monti S, Coppola V, Agricola E, Mottola G, Miniati M, Picano
Usefulness of ultrasound lung comets as a nonradiologic sign of extravascular lung water. *Am J Cardiol* 2004, **93**:1265–1270.

Score	Number of Comet Tails	EVLW
0	<5	No Signs
1	5-15	Mild
2	15-30	Moderate
3	"/>30	Severe

Table 2. Semiquantitive classification of the Comet Tail Score (CTS)as proposed by Picano and colleagues.

Cotation de la sévérité du syndrome interstitiel

Aspect quantitatif : quadrants postérieurs pour pneumopathie interstitielle

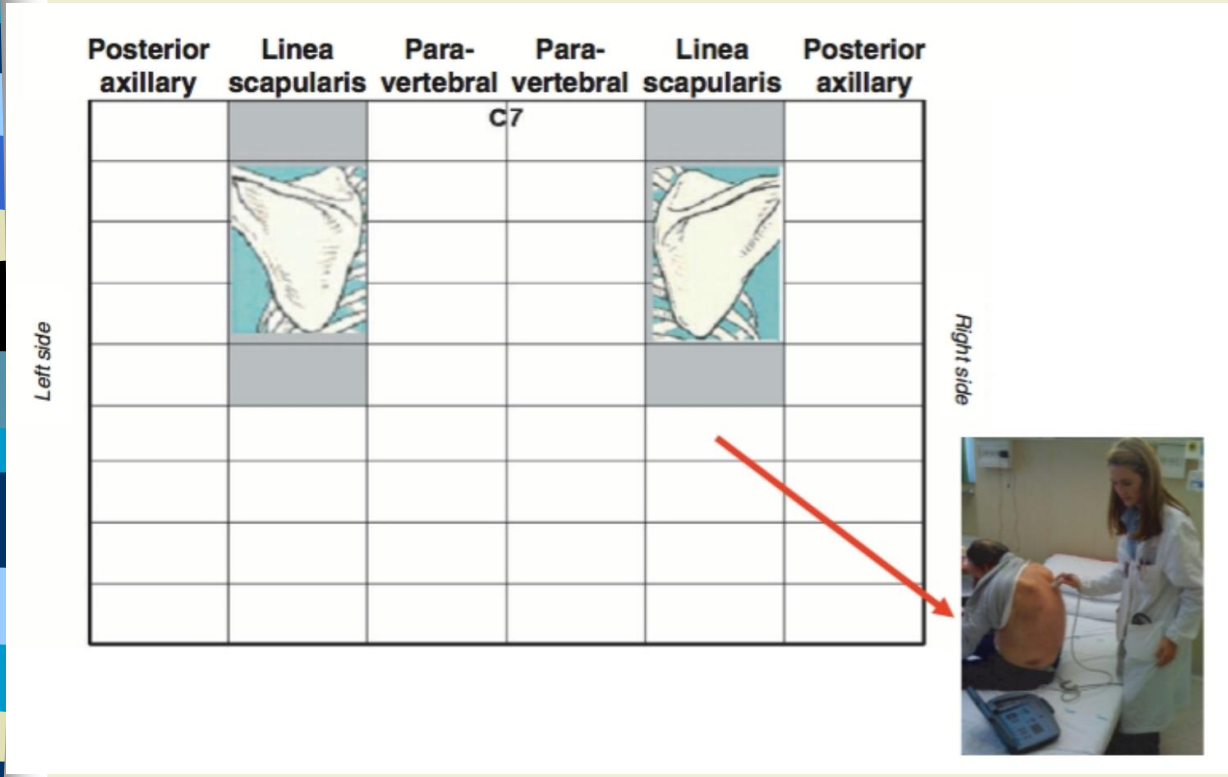

Gargani et al, Rheumatology 2009

Syndromes interstitiels

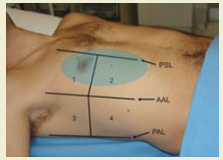

= comptage des lignes B = détection de la congestion pulmonaire infra clinique ?

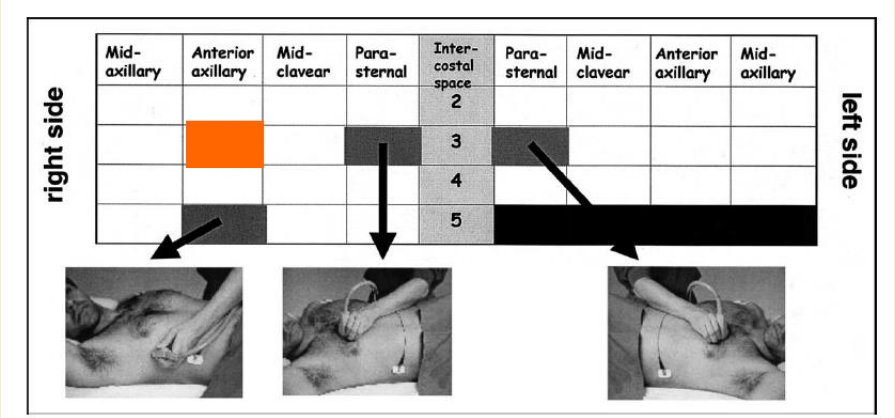

Cardio, N=290, suivis 3-30 mois

Cardio, N=340

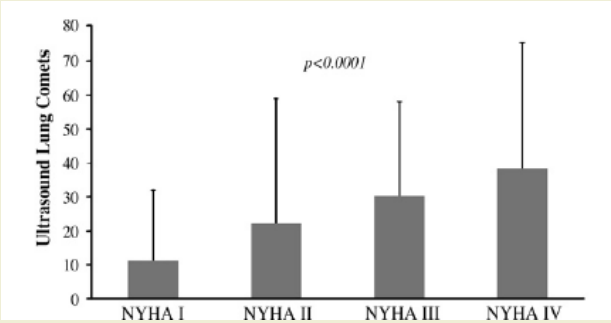

Frassi *Eur J Echocardio* 2007

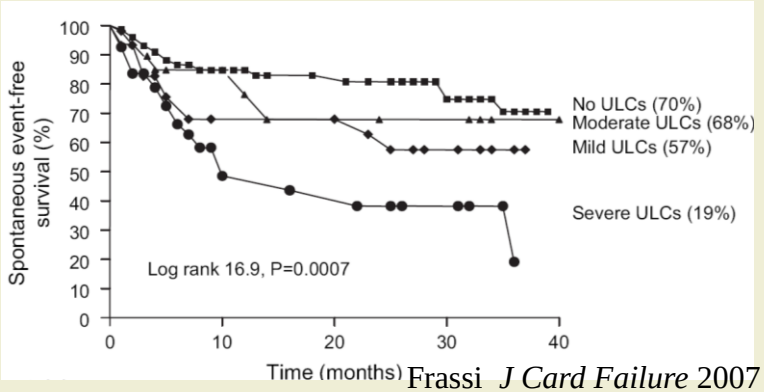

Frassi *J Card Failure* 2007

Cardio, N=100, suivis 6 mois

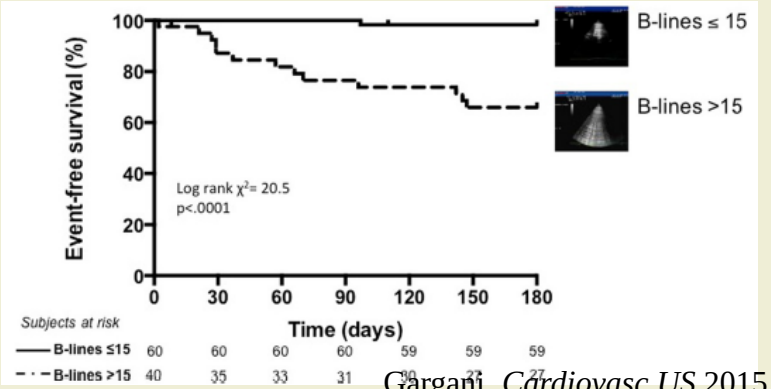

Gargani *Cardiovasc US* 2015

Monitorage déplétion

- Dialyse guidée par ultra-sons, prévention des complications graves

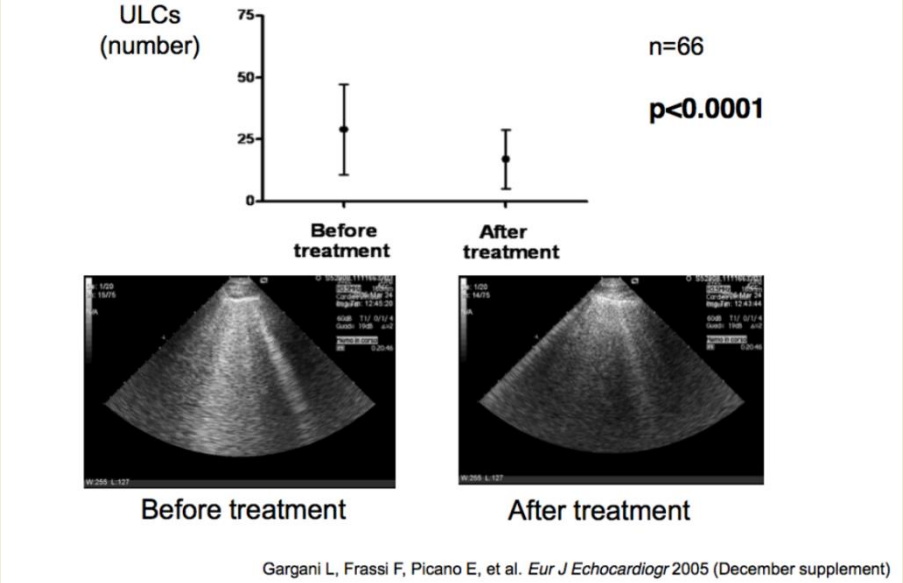

Gargani L, Frassi F, Picano E, et al. *Eur J Echocardiogr* 2005 (December supplement)

Clin J Am Soc Nephrol. 2016 Nov 7;11(11):2005-2011. Epub 2016 Sep 22.

The Agreement between Auscultation and Lung Ultrasound in Hemodialysis Patients: The LUST Study.

Torino C[1], Gargani L[1], Sicari R[1], Letachowicz K[1], Ekart R[1], Fliser D[1], Covic A[1], Siamopoulos K[1], Stavroulopoulos A[1], Massy ZA[1], Fiaccadori E[1], Caiazza A[1], Bachelet T[1], Slotki I[1], Martinez-Castelao A[1], Coudert-Krier MJ[1], Rossignol P[1], Gueler F[1], Hannedouche T[1], Panichi V[1], Wiecek A[1], Pontoriero G[1], Sarafidis

Semin Dial. 2017 Jan;30(1):6-9. doi: 10.1111/sdi.12559. Epub 2016 Nov 6.

Lung Ultrasound in the Management of Fluid Volume in Dialysis Patients: Potential Usefulness.

Zoccali C[1].

Syndromes interstitiels

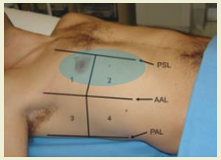

= comptage des queues de comètes

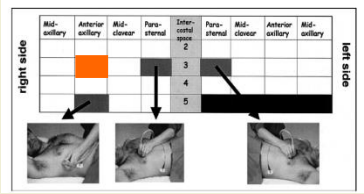

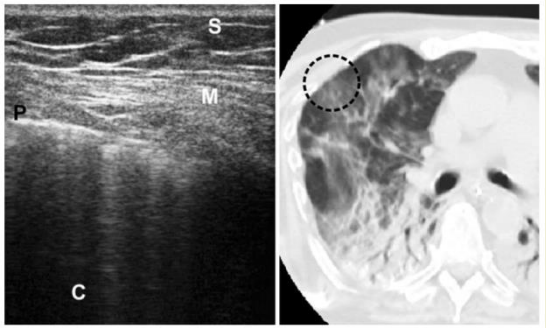

En réanimation, N=20

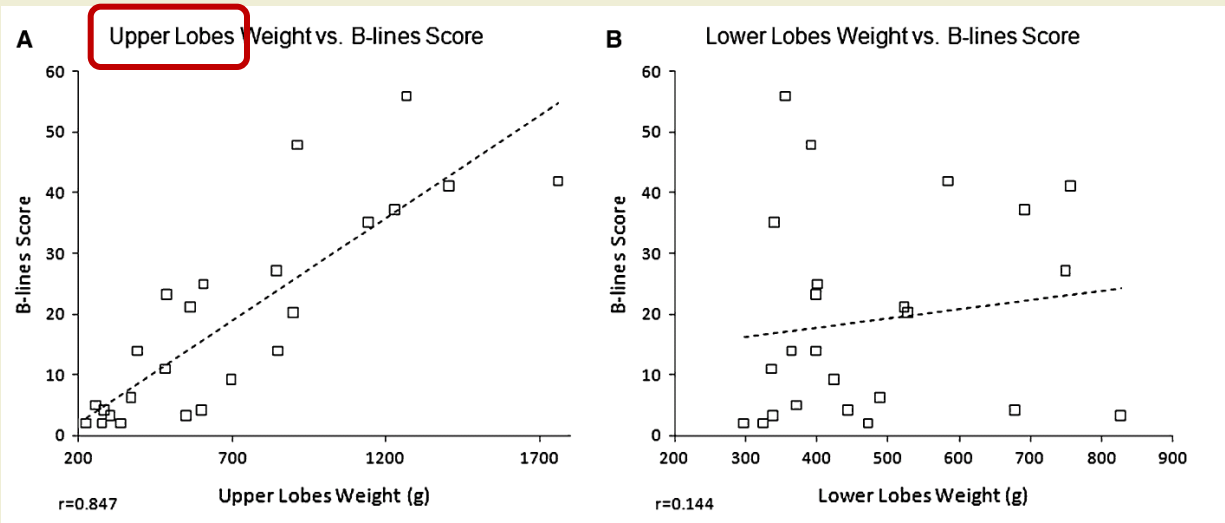

Baldi *ICM* 2013

CONCLUSION

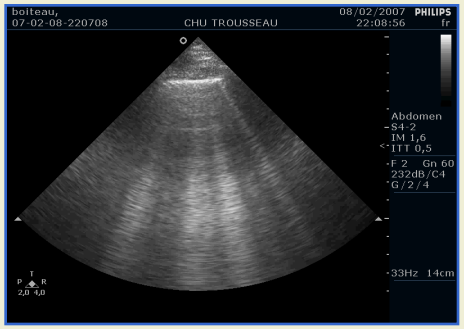

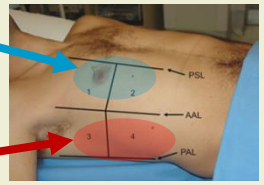

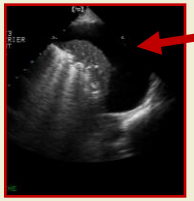

- Identifier :
- Ligne B = 7 caractéristiques
- Sd interstitiel : ≥ 3 lignes B par quadran sur ≥ 2 quadrans du même coté

- Différencier

- Quantifier = diagnostic, pronostic, monitorage et dépistage de sub OAP cardiogéniques infracliniques