TUSAR région Ouest
Pneumothorax

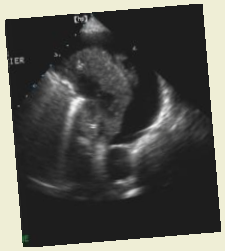

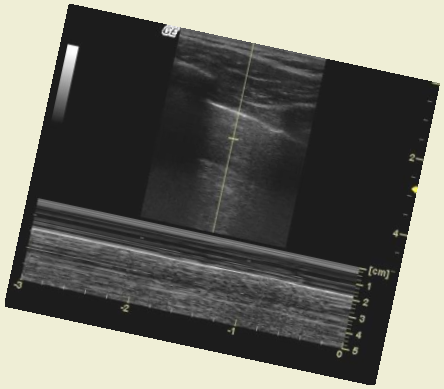

Pr F. Remérand
Pôle Anesthésie-Réanimation SAMU
C.H.R.U. de Tours
f.remerand@chu-tours.fr

08 décembre 2023

Pas de conflit d'intérêt.

difficile ? Artefact sur artefact…

Diagnostic des pneumothorax :

Galbois *Chest* 2010

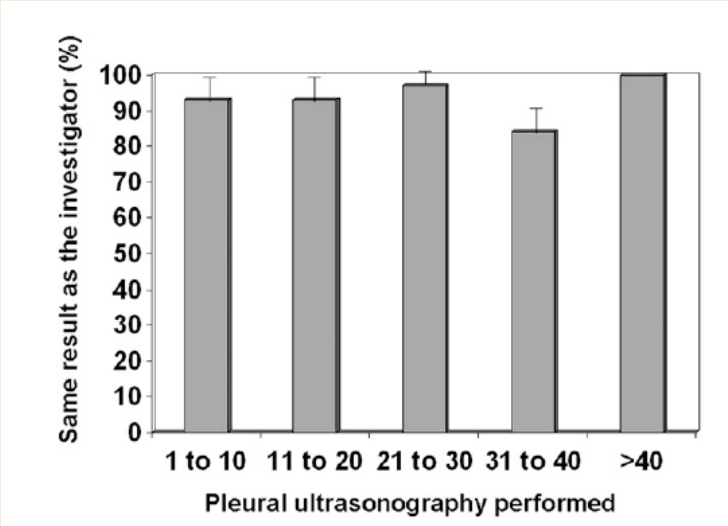

Facile à écarter,

un peu moins à affirmer

Écarter un pneumothorax

Écho >> RP :

Le diagnostic de pneumothorax est mieux éliminé par l'échographie pulmonaire que par la radiographie pulmonaire de face en position allongée (*recommandation de haut niveau, degré de consensus élevé, niveau de preuve A*)

Volpicelli *ICM* 2012

Sur des séries de respectivement 176, 135, 109, 79 et 27 patients polytraumatisés (comprenant respectivement 53, 29, 25, 22 et 11 pneumothorax),
la VPN de l'échographie pulmonaire pour diagnostiquer un pneumothorax était de 99, 96, 99, 93 et 100%,
celle de la RP était de 90, 84, 94, 79 et 70%.

Écarter un pneumothorax

Écho >> RP :

L'échographie pulmonaire est plus performante que la radiographie pulmonaire de face <u>en position allongée</u> pour le diagnostic de pneumothorax (*recommandation de haut niveau, degré de consensus très élevé, niveau de preuve B*)

Volpicelli *ICM* 2012

Sur des séries de respectivement 176, 135, 109, 79 et 27 patients polytraumatisés (comprenant respectivement 53, 29, 25, 22 et 11 pneumothorax),
la sensibilité de l'échographie pulmonaire pour diagnostiquer un pneumothorax était de 98, 86, 92, 82 et 100%,
celle de la RP était de 76, 28, 52, 32 et 36%

Intensive Care Med (2012) 38:577–591
DOI 10.1007/s00134-012-2513-4

CONFERENCE REPORTS AND EXPERT PANEL

International evidence-based recommendations for point-of-care lung ultrasound

Giovanni Volpicelli
Mahmoud Elbarbary
Michael Blaivas
Daniel A. Lichtenstein
Gebhard Mathis
Andrew W. Kirkpatrick
Lawrence Melniker
Luna Gargani
Vicki E. Noble
Gabriele Via
Anthony Dean
James W. Tsung
Gino Soldati
Roberto Copetti
Belaid Bouhemad
Angelika Reissig
Eustachio Agricola
Jean-Jacques Rouby
Charlotte Arbelot
Andrew Liteplo
Ashot Sargsyan
Fernando Silva
Richard Hoppmann
Raoul Breitkreutz
Armin Seibel
Luca Neri
Enrico Storti
Tomislav Petrovic
International Liaison Committee on Lung Ultrasound (ILC-LUS) for the International Consensus Conference on Lung Ultrasound (ICC-LUS)

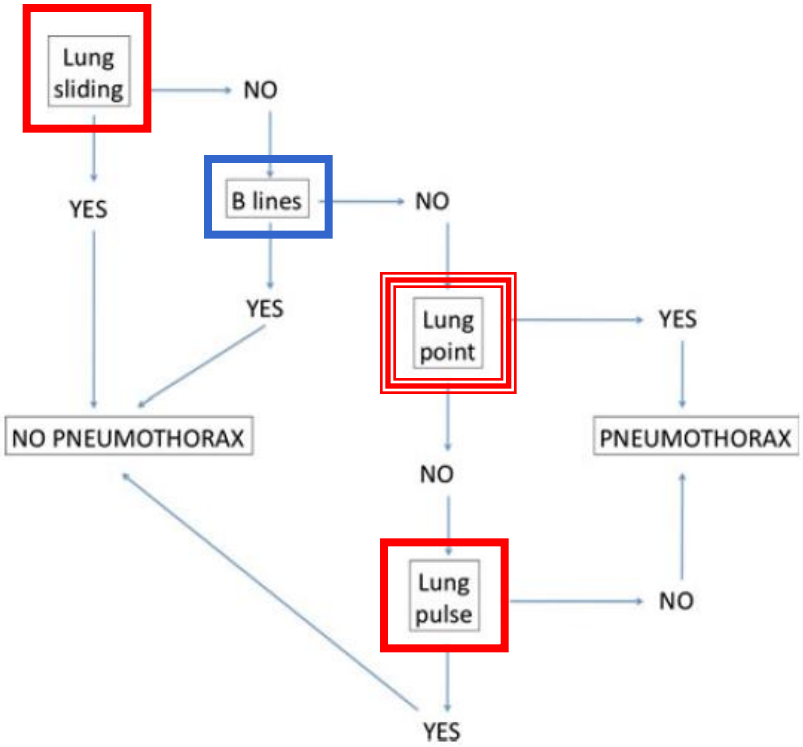

Les 3 (4?) signes cardinaux du PNO



1) glissement pleural (ou lung pulse) = pas de PNO

2) syndrome interstitiel = pas de PNO

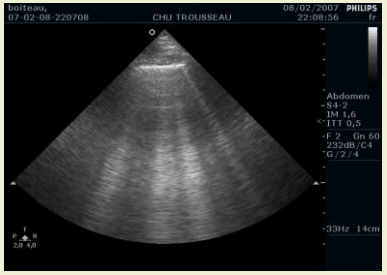

3) point poumon = pathognomonique du PNO

Les limites de l'échographie pleuropulmonaire

1) Emphysème sous cutané
= écho impossible

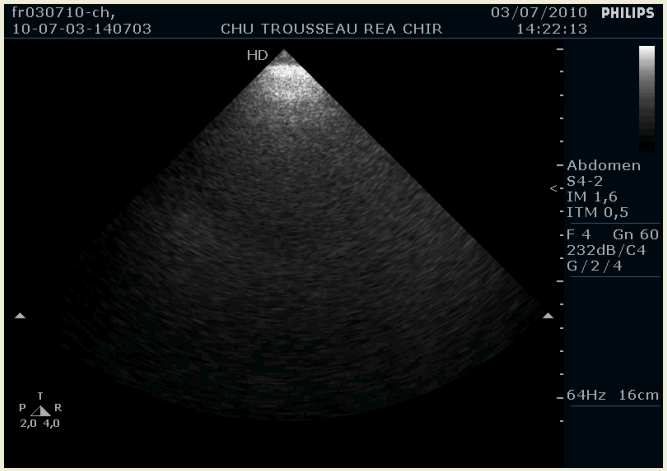

2) Choix techniques

Sonde linéaire pour l'examen antérieur ?

Sonde linéaire

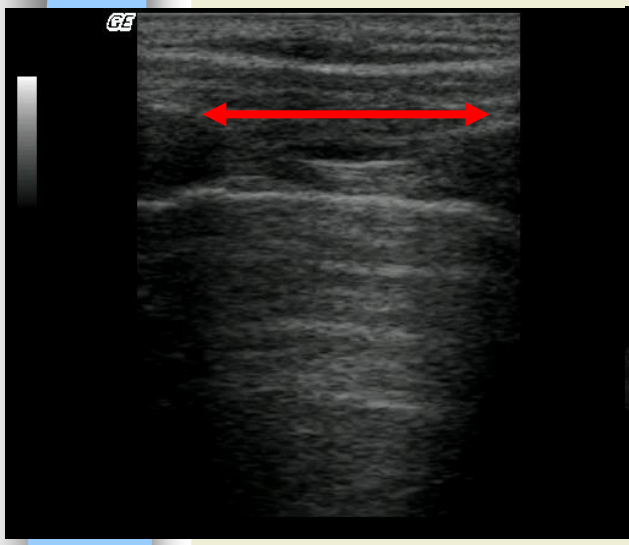

Sonde abdo

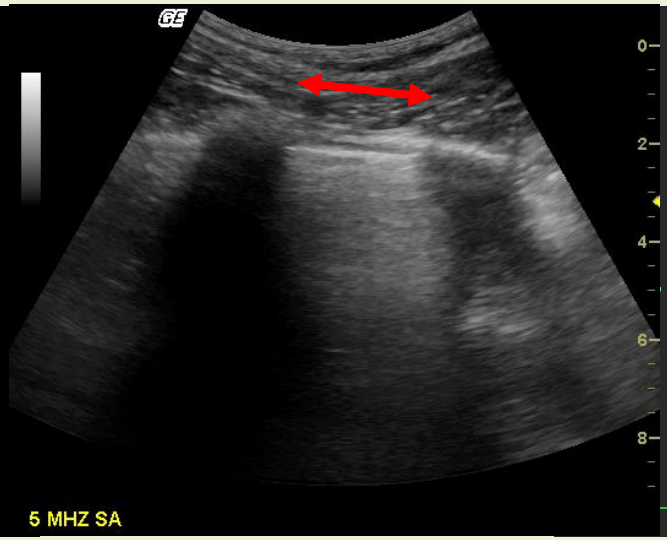

Sonde cardio

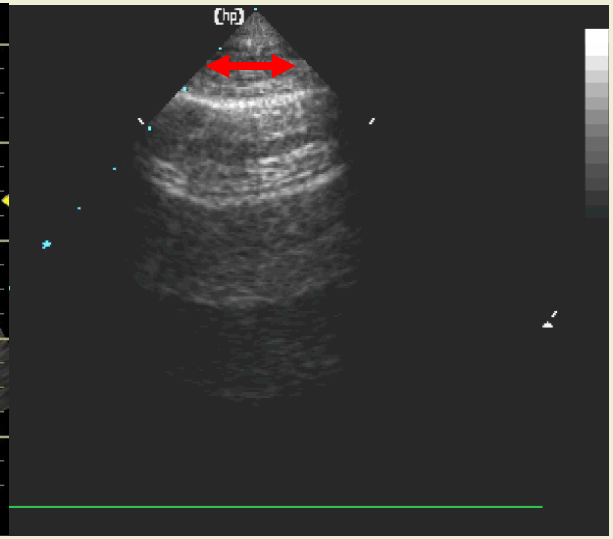

Profondeur 10 cm environ ; focale sur la plèvre +++

3) les régions à explorer

Antéro basal (allongé), ± antéro apical (assis) et en latéral

B-D1-S2 (strong: level A)

- In the supine patient, the sonographic technique consists of exploration of the least gravitationally dependent areas progressing more laterally.
- Adjunct techniques such as M-mode and color Doppler may be used.

Volpicelli *ICM* 2012

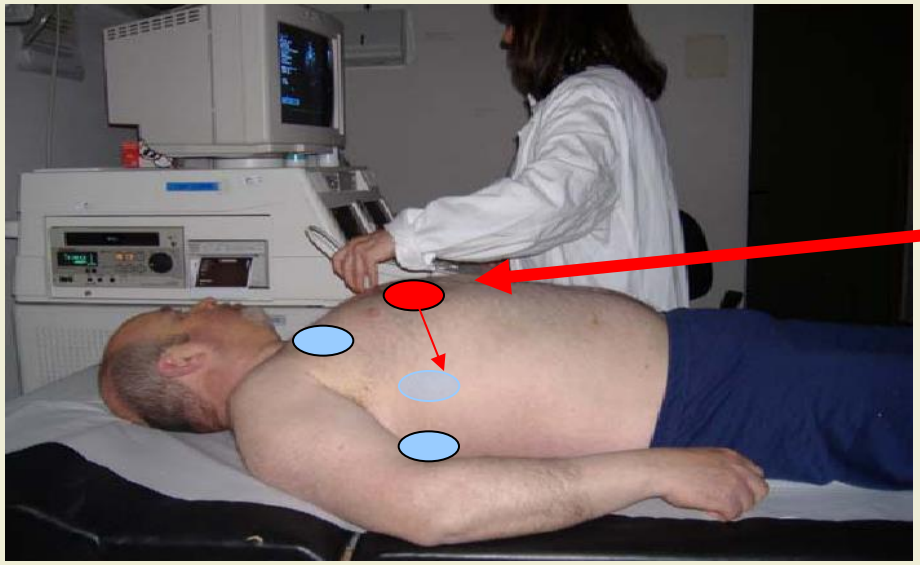

Zone
non dépendante +++

4) Repérage de la ligne pleurale

a) En présternal :
cartilages costaux

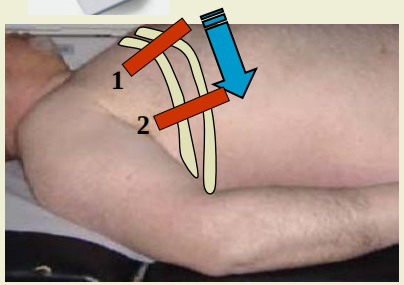

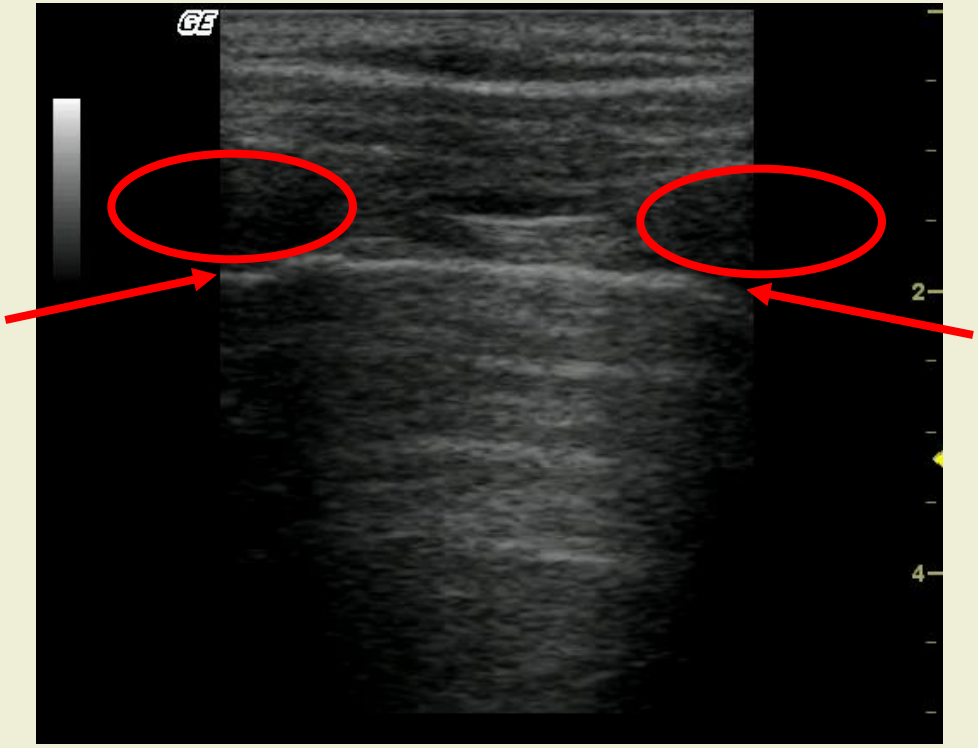

4) Repérage de la ligne pleurale

b) En latéral / postérieur :
ombre acoustique des côtes

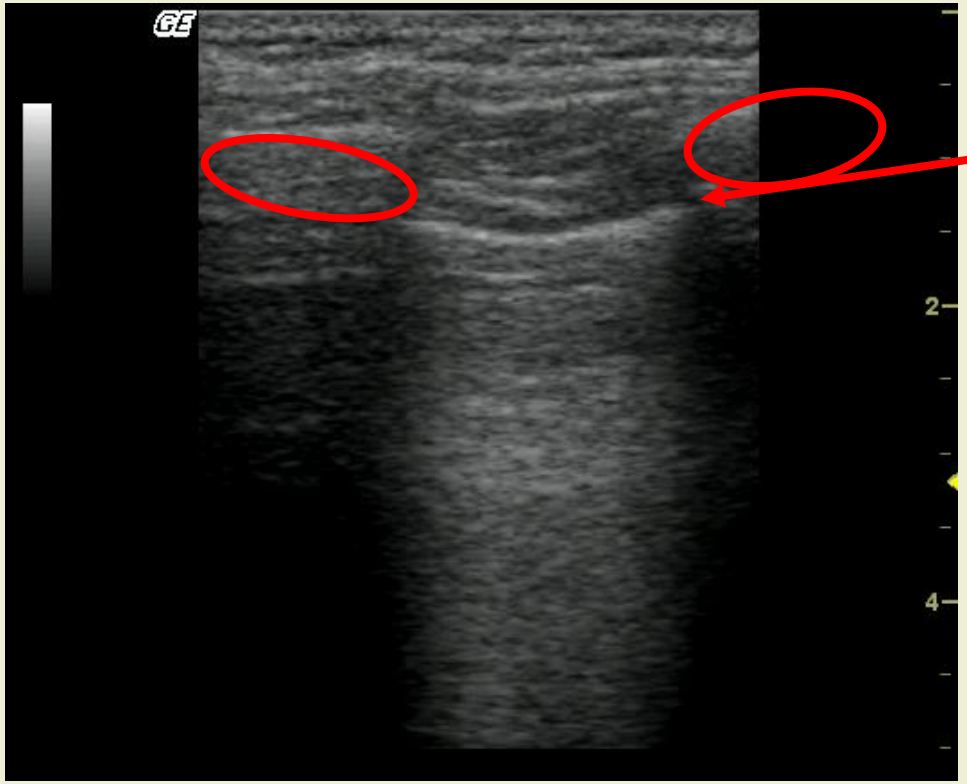

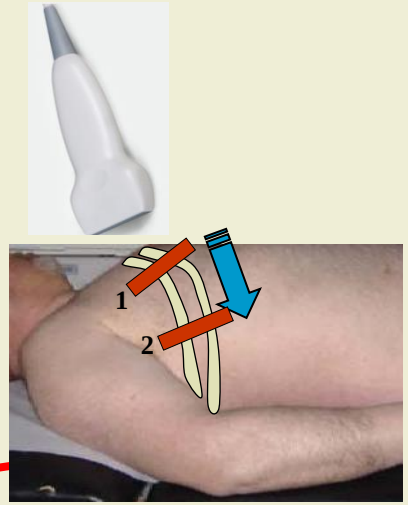

5) Glissement pleural

optimisation

Image grand axe

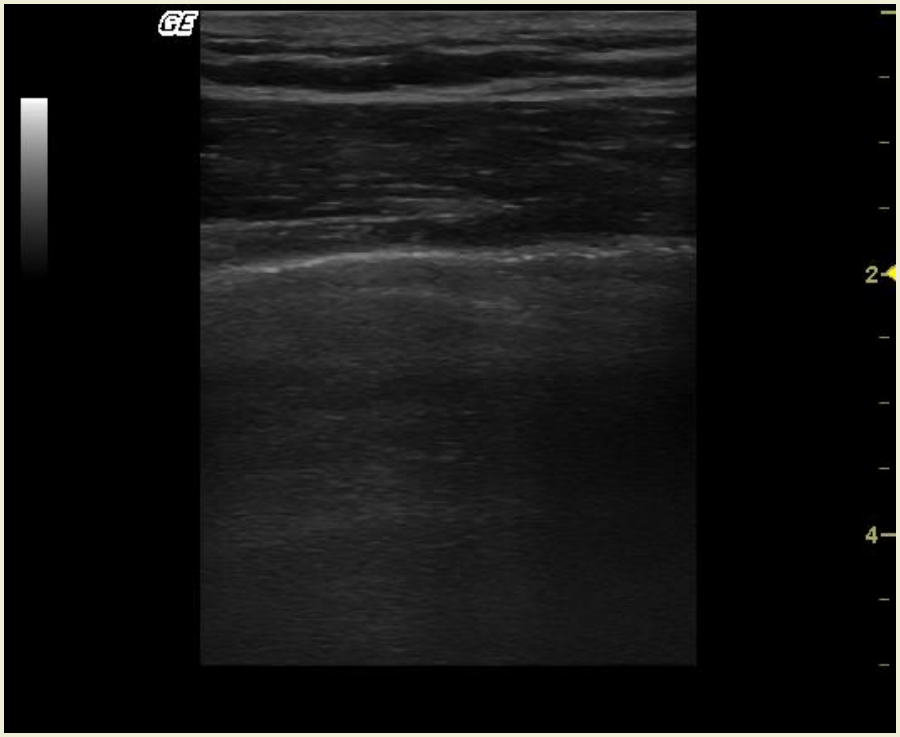

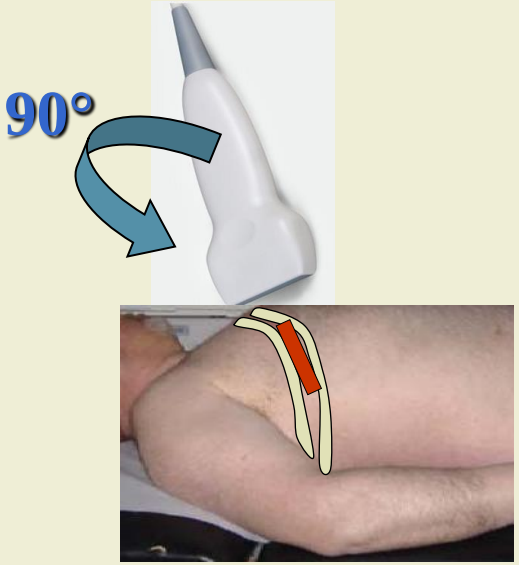

Intensive Care Med (2012) 38:577–591
DOI 10.1007/s00134-012-2513-4

CONFERENCE REPORTS AND EXPERT PANEL

Giovanni Volpicelli
Mahmoud Elbarbary
Michael Blaivas
Daniel A. Lichtenstein
Gebhard Mathis
Andrew W. Kirkpatrick
Lawrence Melniker
Luna Gargani
Vicki E. Noble
Gabriele Via
Anthony Dean
James W. Tsung
Gino Soldati
Roberto Copetti
Belaid Bouhemad
Angelika Reissig
Eustachio Agricola
Jean-Jacques Rouby
Charlotte Arbelot
Andrew Liteplo
Ashot Sargsyan
Fernando Silva
Richard Hoppmann
Raoul Breitkreutz
Armin Seibel
Luca Neri
Enrico Storti
Tomislav Petrovic
International Liaison Committee on Lung Ultrasound (ILC-LUS) for the International Consensus Conference on Lung Ultrasound (ICC-LUS)

International evidence-based recommendations for point-of-care lung ultrasound

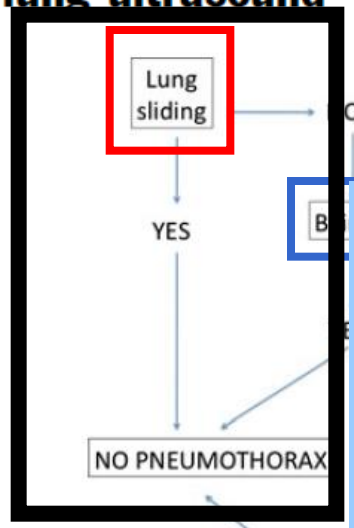

Glissement pleural présent = pas de PNO

6) Documentation du glissement pleural

Présent :

Absent :

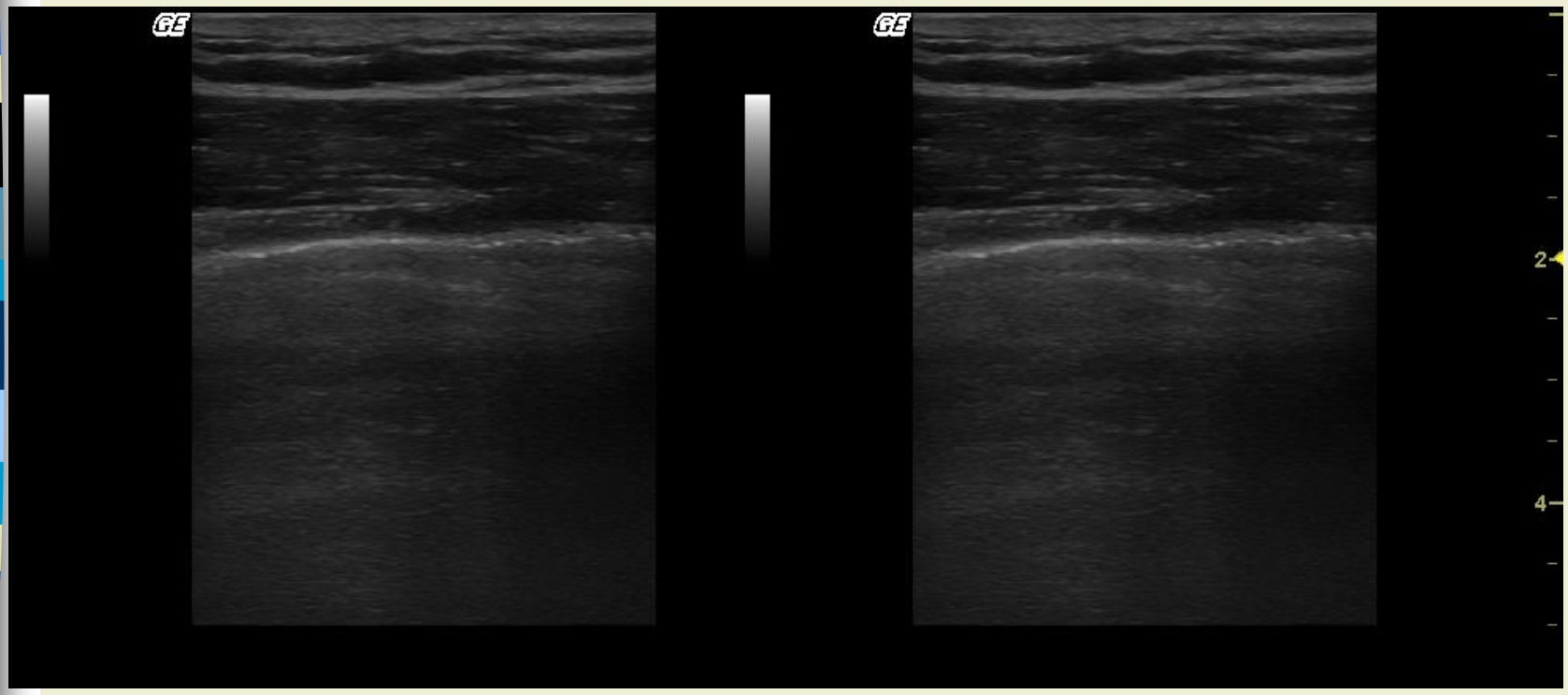

Documentation du glissement pleural

Mode B

Mode TM

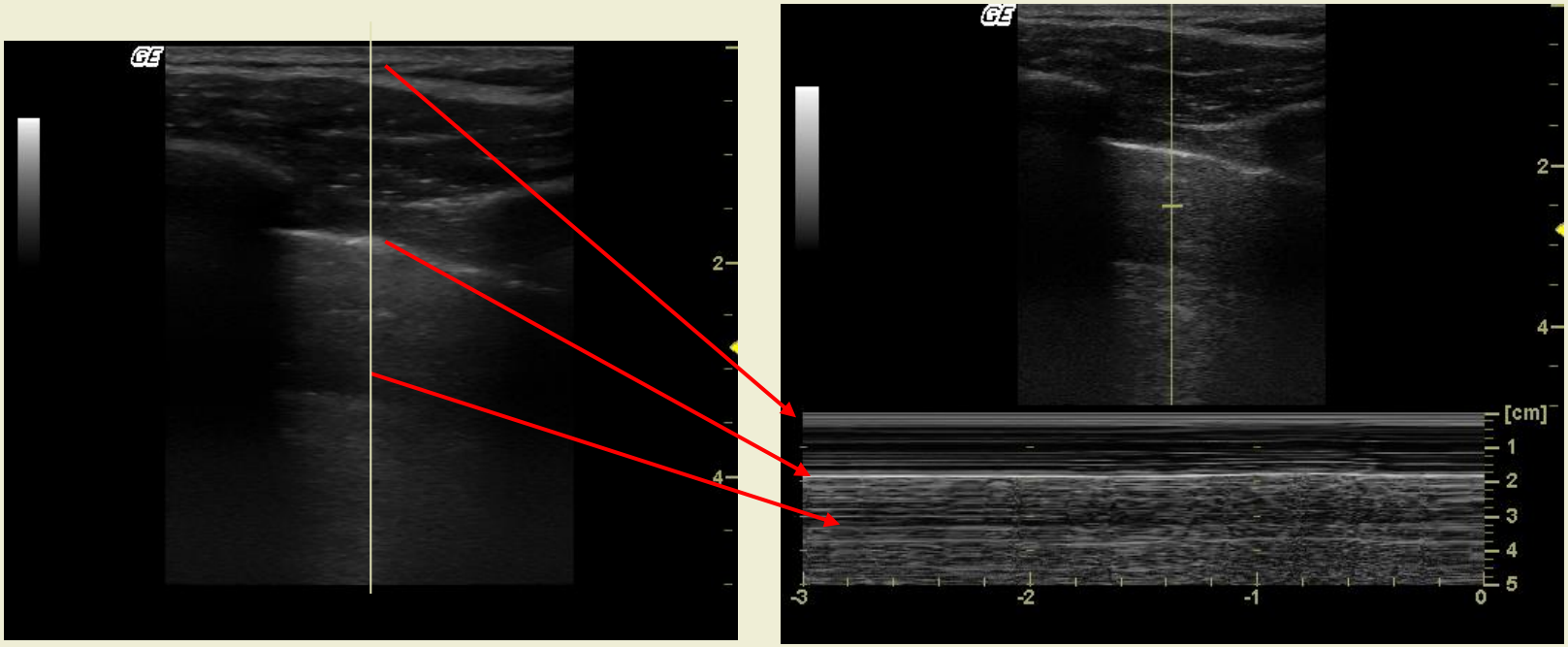

Glissement pleural: optimisation… et documentation

En mode TM :
Aspect normal

En mode TM :
Apnée

Pneumothorax : iconographie

En mode TM :
normal

En mode TM :
pneumothorax

Pneumothorax : iconographie

En mode TM :
normal

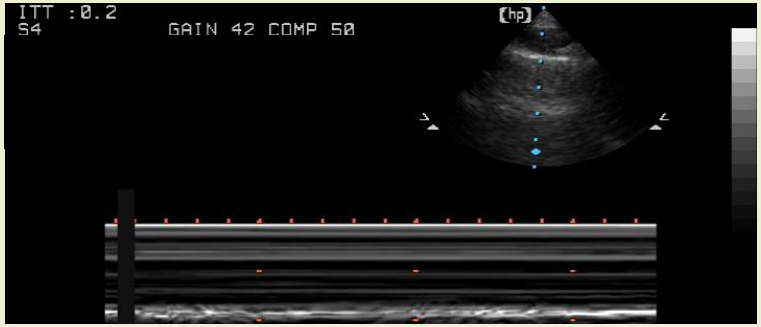

En mode TM :
pneumothorax

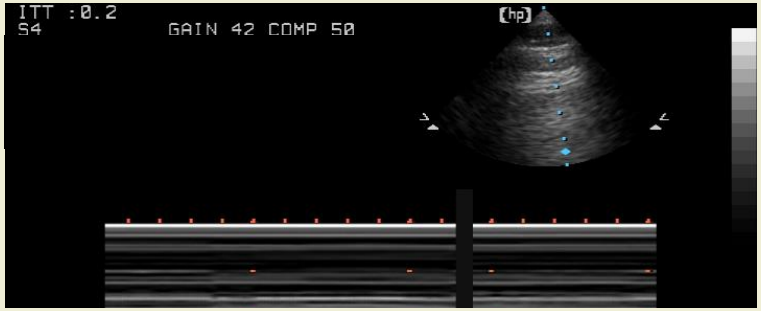

Pneumothorax : iconographie

En mode TM :
Aspect normal

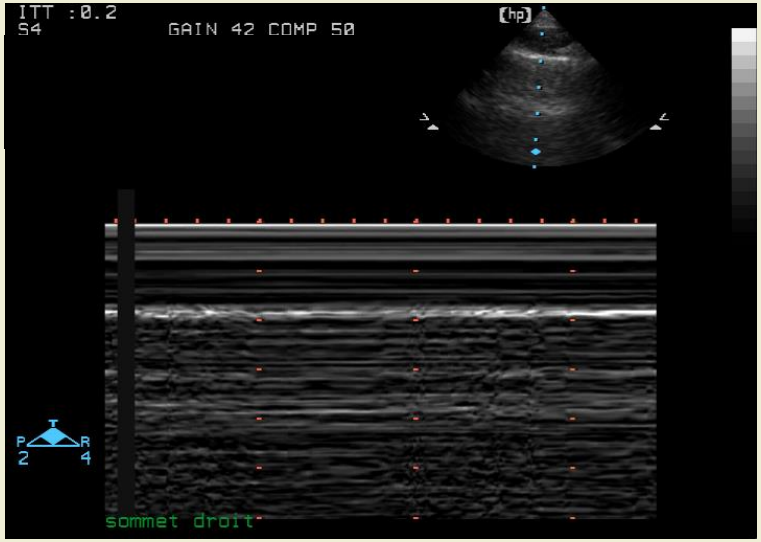

En mode TM :
pneumothorax

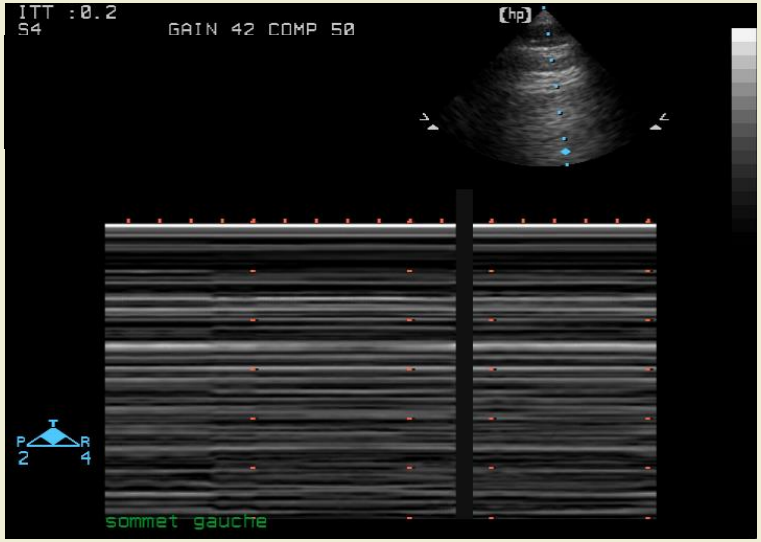

7) Glissement pleural: difficile si

1) Mouvements pariétaux importants:
Toux, tachypnée, agitation

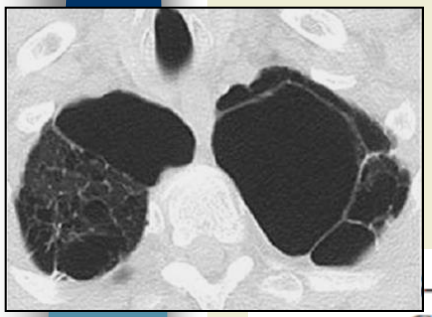

2) Une bulle d'emphysème abolie
le glissement pleural dans 6/19 = 30% des cas ???

—*Positional Distribution of Pleural Sliding for COPD Patients Whose Appearances Were Misinterpreted (Five Patients, Six Hemithoraces) by the Experienced Observer**

Spaces	Patient No. 1	2	3	4	5	6
Second intercostal	–	–	–	–	–	+
Fourth intercostal	–	–	–	+	+	+
Sixth intercostal	+	+	+	+	+	–

*+ indicates denotes pleural movement; – indicates the absence of pleural movement.

19 patients … assis !!!
Donc faux positifs = 0/19
si patients allongés…

Slater *Chest* 2006

Glissement pleural: « difficile » si :

3) Rigidité pulmonaire
sur poumon malade …

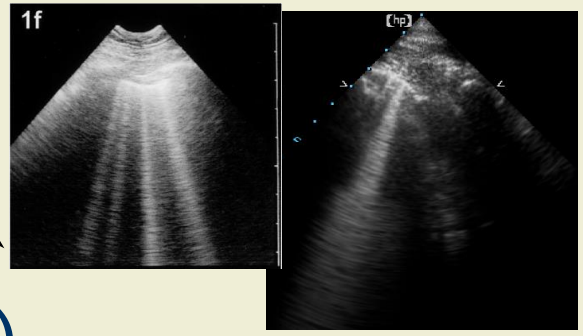

4) poumon sain immobile (G>D)

…

normal

« lung pulse »

PNO

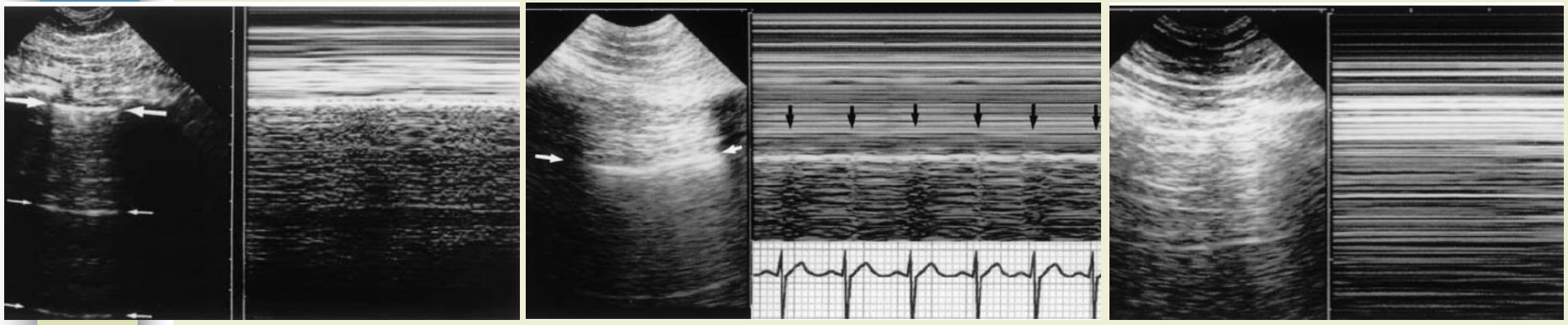

Mode TM

Lichtenstein *ICM* 2003

Glissement pleural: « difficile » si :

5) Adhérences pleurales ?

Peu probable car en post opératoire :

J30-45

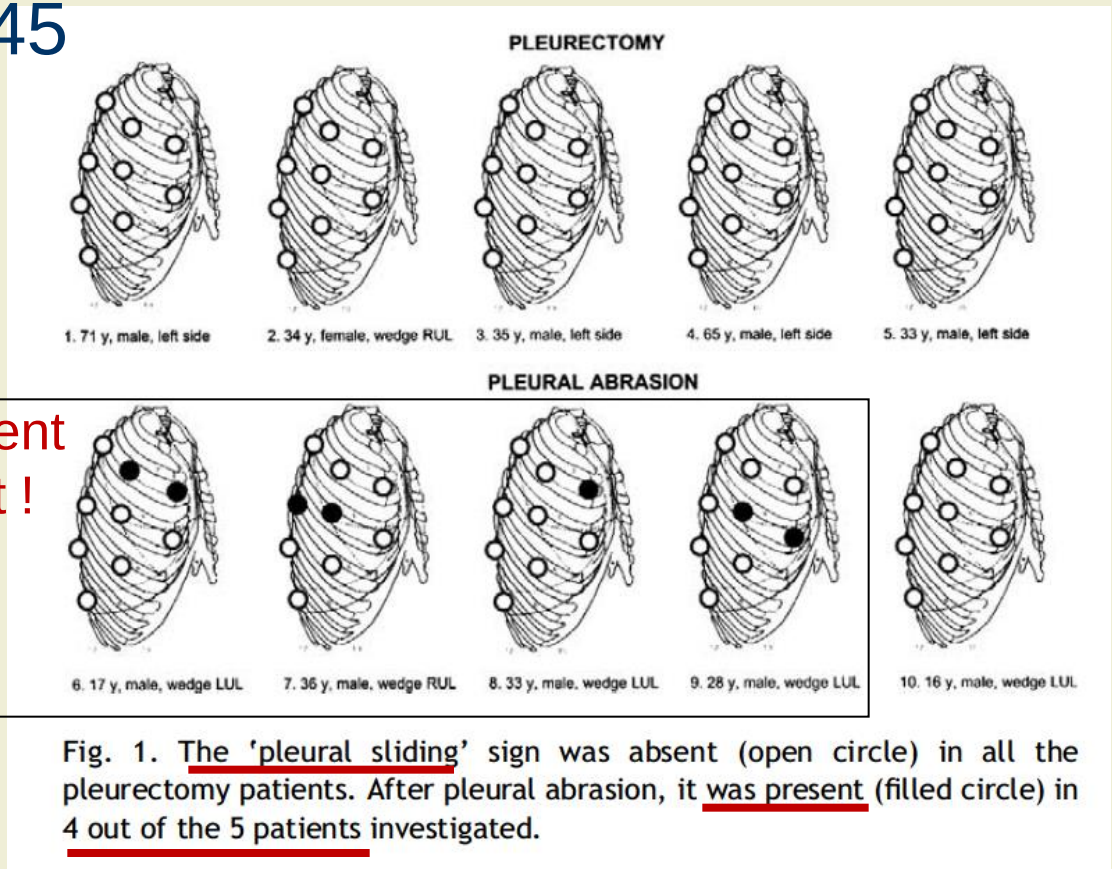

Glissement présent !

Fig. 1. The 'pleural sliding' sign was absent (open circle) in all the pleurectomy patients. After pleural abrasion, it was present (filled circle) in 4 out of the 5 patients investigated.

Leo *EJCTS* 2005

8) Pneumothorax : Diagnostic positif

normal = artefact gazeux mobile avec la respiration
pneumothorax = artefact gazeux fixe avec la respiration
= abolition du glissement pleural

En mode B :
normal

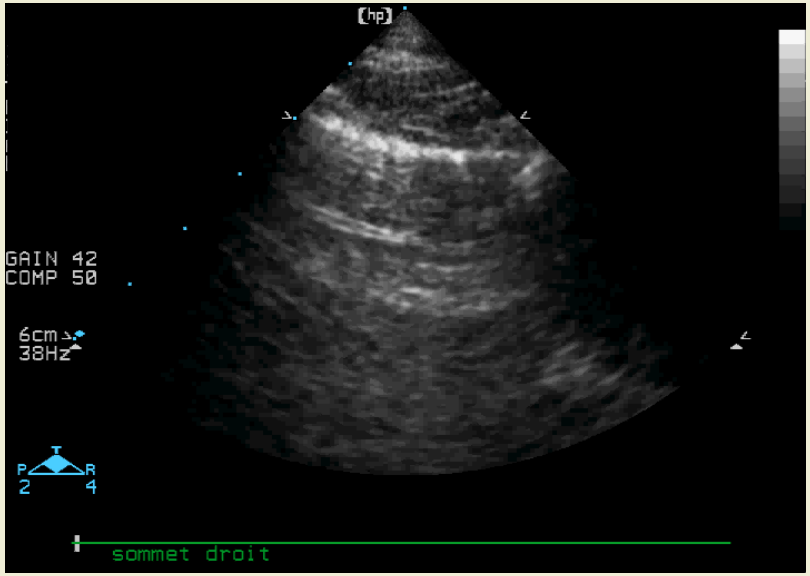

En mode B :
pneumothorax

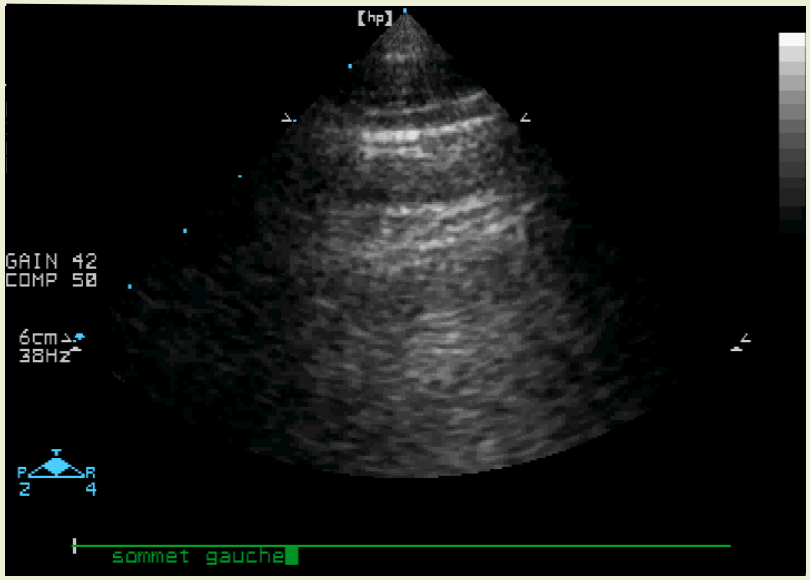

Pneumothorax : Diagnostic positif

En limite de pneumothorax,

inspiration

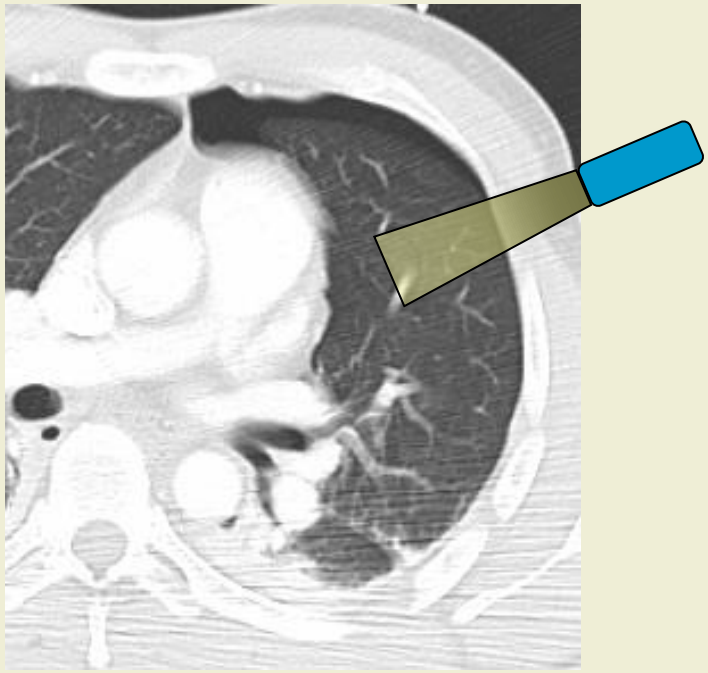

expiration

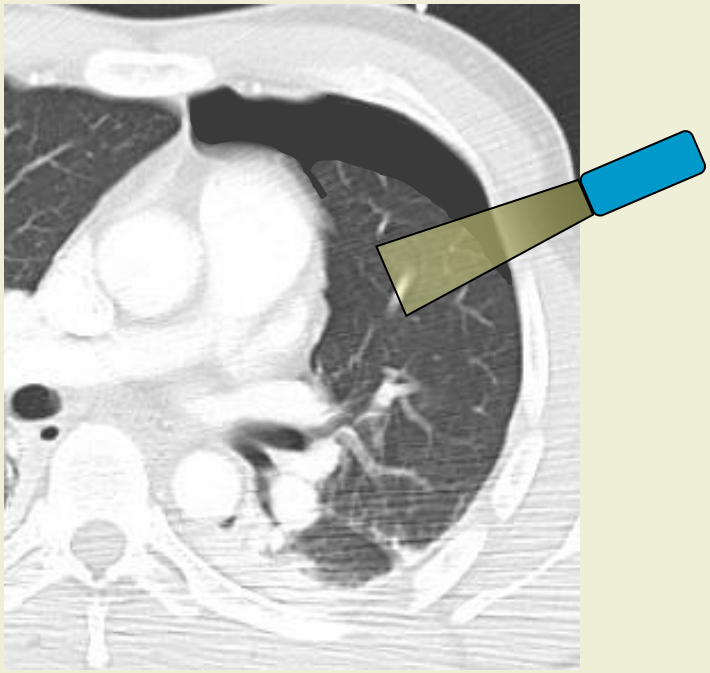

Pneumothorax : Diagnostic positif

En limite de pneumothorax, alternance d'images

normales = artefact gazeux mobile avec la respiration

pneumothorax = artefact gazeux fixe avec la respiration

= point poumon = point P = signe du rideau

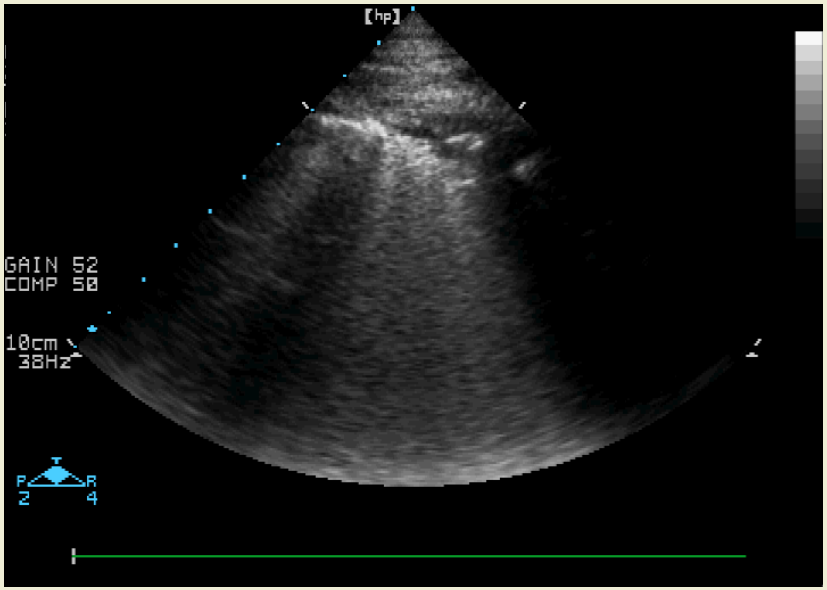

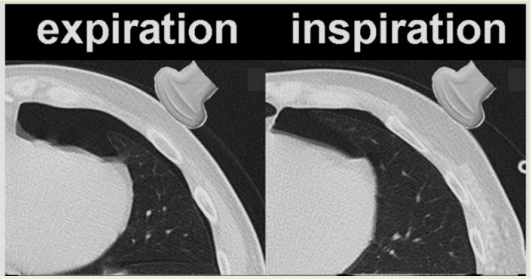

Les pneumothorax

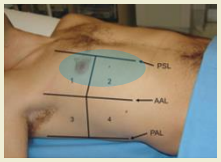

en mode B

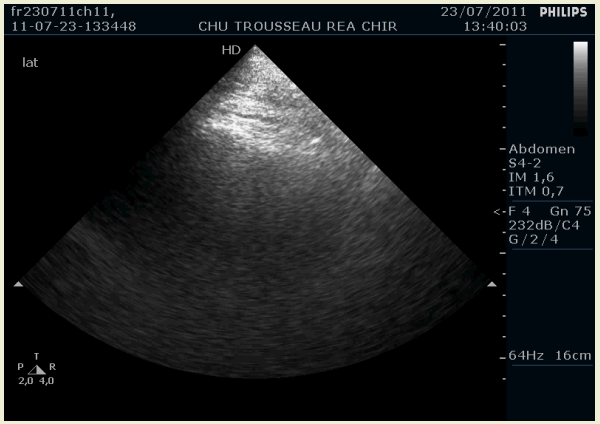

« signe du rideau » ou
« point poumon »

en limite du pneumothorax:

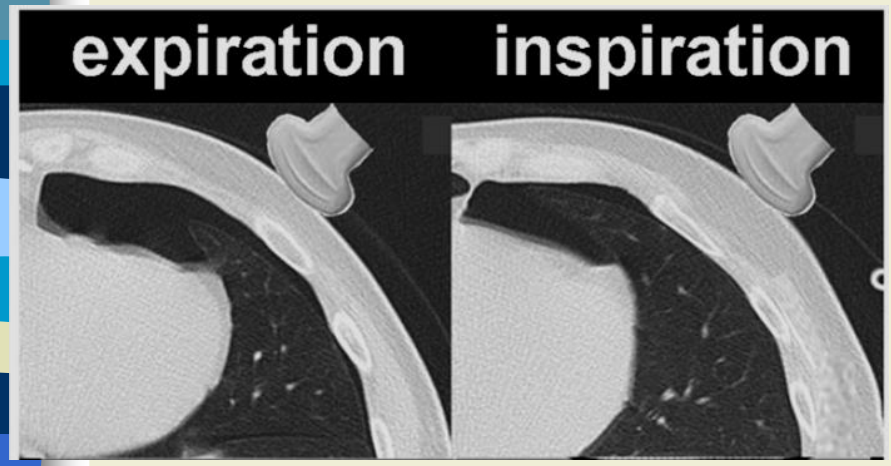

Galbois *Chest* 2010

en mode TM en mode B

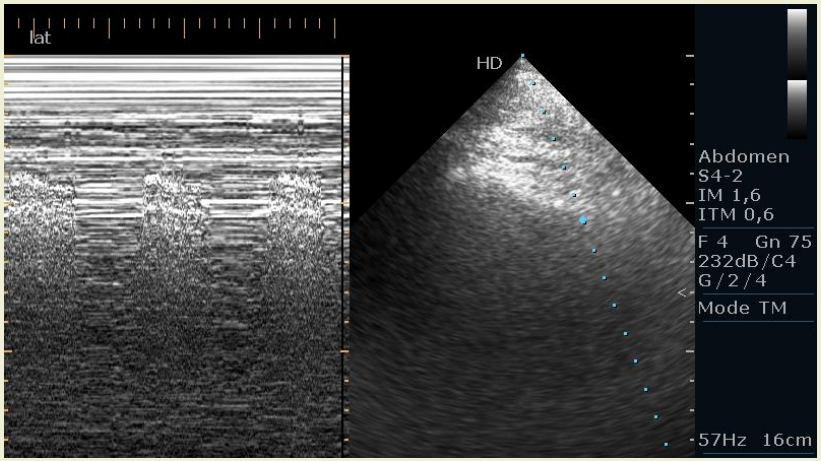

En limite du poumon normal, alternance d'images

« normales » = artefact gazeux mobile avec la respiration

rate ou foie = artefact tissulaire mobile avec la respiration

= point poumon « physiologique »

L'épaisseur du poumon n'est pas mesurable

Diaphragme invisible (sauf en trans-abdominal)

foie

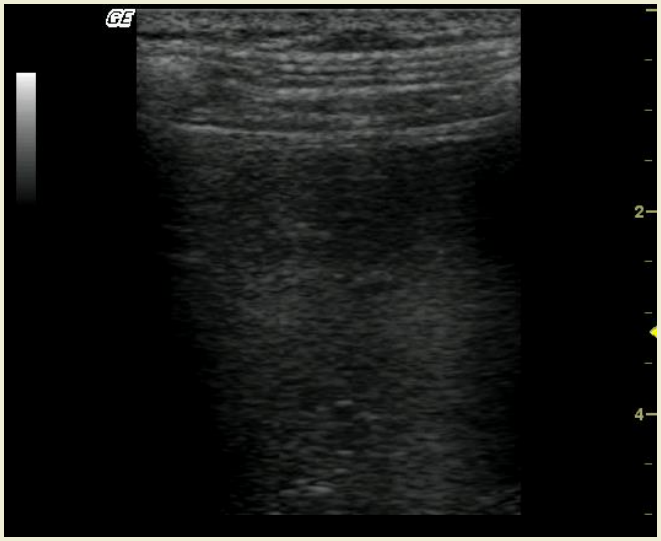

rate

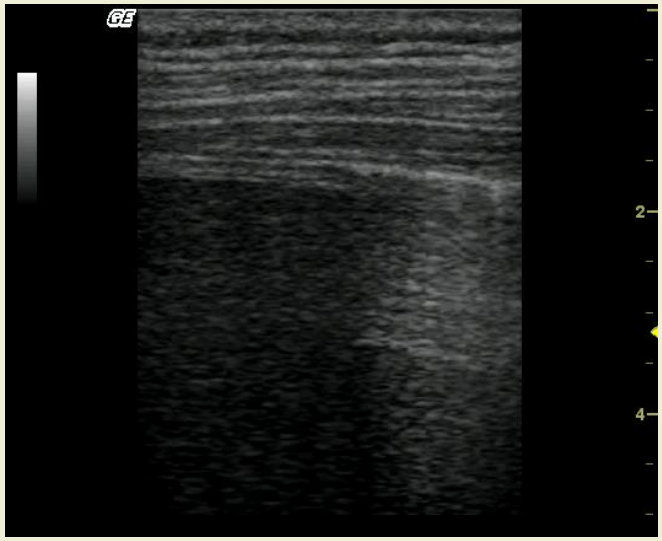

Pneumothorax :

Limites de l'échographie :
analyse <u>quantitative</u> difficile

Point poumon

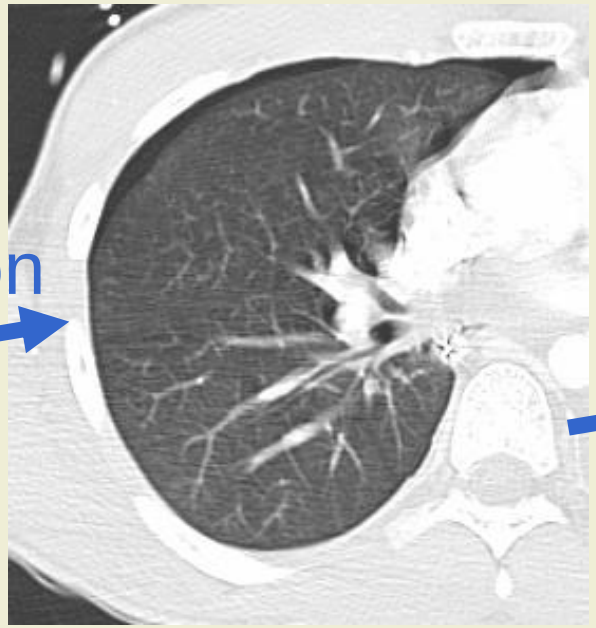

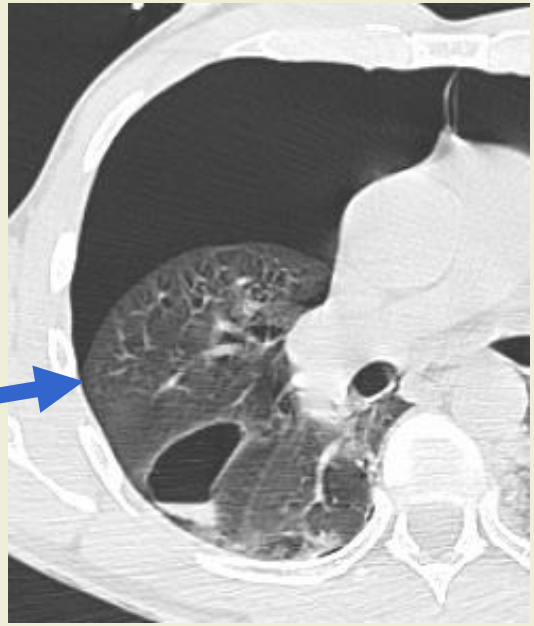

Pneumothorax :

Si poumon non rigide

analyse <u>semi quantitative</u> possible :

Points poumon

Petit PNO antérieur

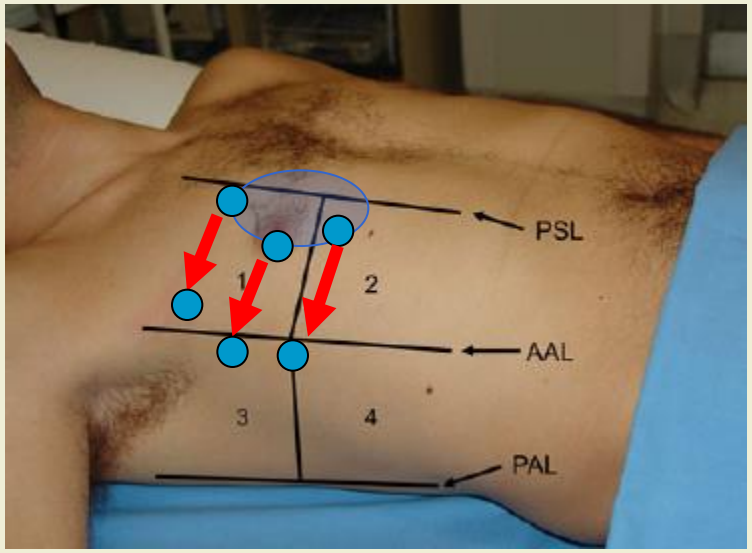

Extension du PNO

Pneumothorax :

Si poumon non rigide
analyse <u>semi quantitative</u> possible :

Points poumon

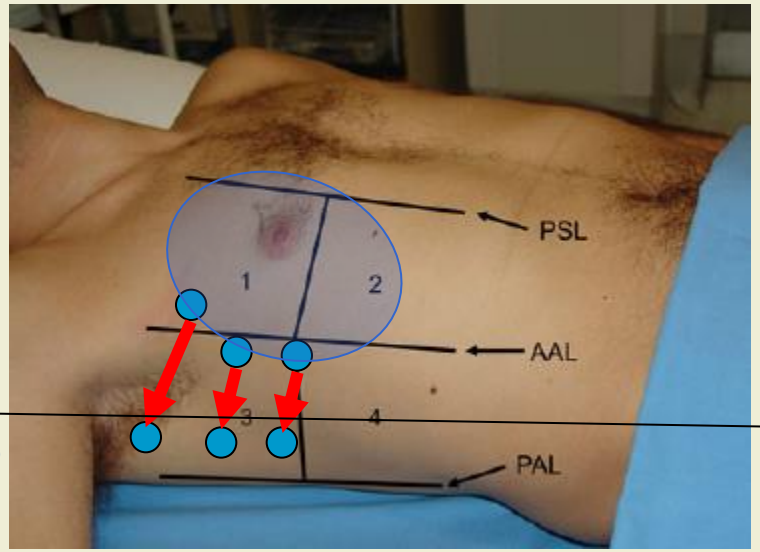

Extension du PNO

PNO complet / RP

Ligne axillaire moyenne

Volpicelli *ICM* 2014

Pneumothorax :

Si poumon non rigide

analyse <u>semi quantitative</u> possible :

58 PNO / TDM

Points poumon

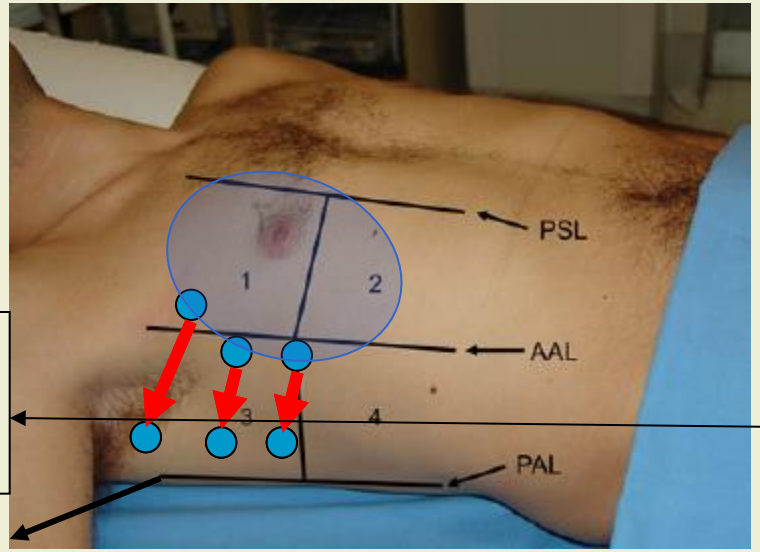

Extension du PNO

PNO complet / RP

PNO > 15% / TDM

PNO > 30% / TDM

Ligne axillaire moyenne

PNO > 15 % : Se 83%, Sp 82%, VPP 77%, VPN 88%

PNO > 30 % : Se 90%, Sp 81%, VPP 50%, VPN 98%

Volpicelli *ICM* 2014

Pneumothorax :

Si poumon non rigide

analyse <u>semi quantitative</u> possible :

Points poumon

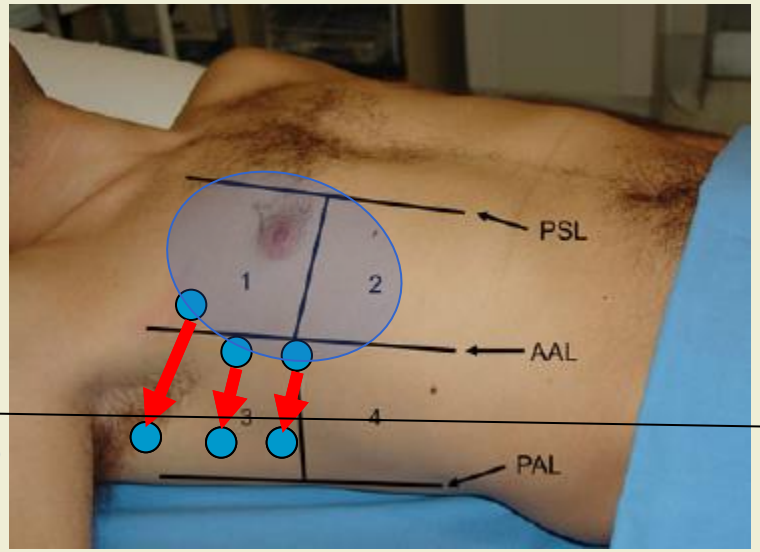

Extension du PNO

PNO complet / RP

Ligne axillaire moyenne

Se 83%, Sp 82%, VPP 77%, VPN 88%

Volpicelli *ICM* 2014

Conclusion :

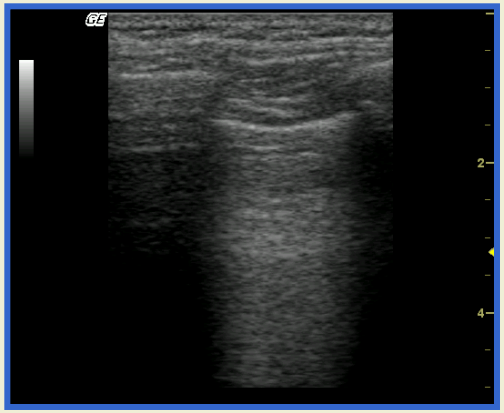

1) glissement pleural,

ou bandes verticales hyperéchogènes

= *pas de PNO*

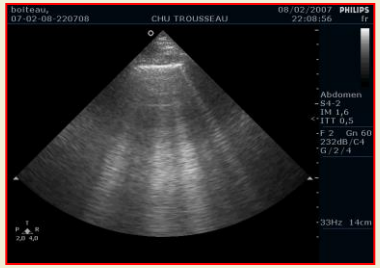

2) point Poumon = *pneumothorax*
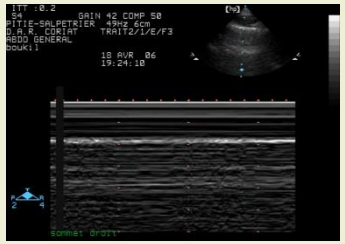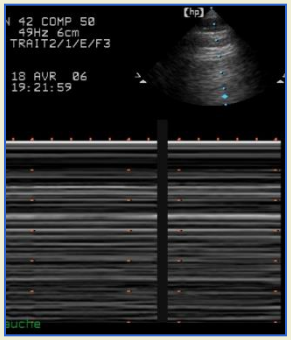
Iconographie = mode TM+++