Abdomen : examen normal

Cours TUSAR Ouest, 16 décembre 2022

Pr REMERAND Francis

Pôle anesthésie Réanimations,

Dr AYOUB Jean

Unité d'échographie générale,

CHRU Trousseau - TOURS

Objectifs

Conférence de consensus ACCP / SRLF

- préparation - installation du patient
- choix de matériel et de sonde
- les coupes à réaliser
- énumérer les organes abdominaux explorables en échographie
- orientation et repérage échoanatomique

Mayo PH, Chest 2009

Table 3—*Technical (Image Acquisition) and Cognitive (Image Interpretation) Elements Required for Competence in Abdominal Ultrasonography*

Assessment for intraperitoneal fluid
Identification of a relatively echo-free space surrounded by typical anatomic boundaries: abdominal wall, diaphragm, liver, gallbladder, spleen, kidney, bladder, bowel, uterus, spinal column, aorta, IVC
Identification of abdominal wall, diaphragm, liver, gallbladder, spleen, kidney, bladder, bowel, uterus, spinal column, aorta, IVC
Identification of characteristic dynamic findings of intraperitoneal fluid, such as diaphragmatic motion, floating bowel, bowel peristalsis, dynamic fluid motion, and respirophasic shape change, compressibility
Characterization of fluid: anechoic; echogenicity (using liver/spleen as reference); homogeneous or heterogeneous; presence of strands/debris/septations
Qualitative assessment of intraperitoneal fluid volume
Recognition of specific limitations of ultrasonography to identify intraperitoneal fluid such as inadequate image quality due to technical limitations, hemoperitoneum, echo-dense purulent fluid
Assessment of the urinary tract
Bladder: identification of bladder, identification of urinary catheter, identification of abnormal bladder contents
Differentiation of distended bladder from ascites
Qualitative assessment of intravesicular volume, identification of overdistention
Kidneys: identification of both kidneys, identification of presence or absence of hydronephrosis, measurement of kidney in longitudinal axis
Assessment of the aorta
Identification of abdominal aorta
Identification of abdominal aortic aneurysm

Préparation - installation idéale…

- Patient à jeun (>6h), decubitus dorsal +/- 35 – 45°

- après un examen CLINIQUE =
  « pas de question, pas de réponse … »
  gestion d'un « incidentalome »

- Examen débrouillage : rapide, réponse oui / non / nsp
- Si NSP = radiologue

- Pour chaque organe = balayage complet

- Compte rendu : différencier aspect écho / interprétation

Matériel

Sonde abdo

Sonde cardio + preset abdo

Sondes linéaires : pour geste invasif

Les principales coupes

Axiales et longitudinales :



A = médiane

B = para médiane interne

C = para médiane

D = para médiane externe

E = latérale

Rappels anatomiques

Foie D G

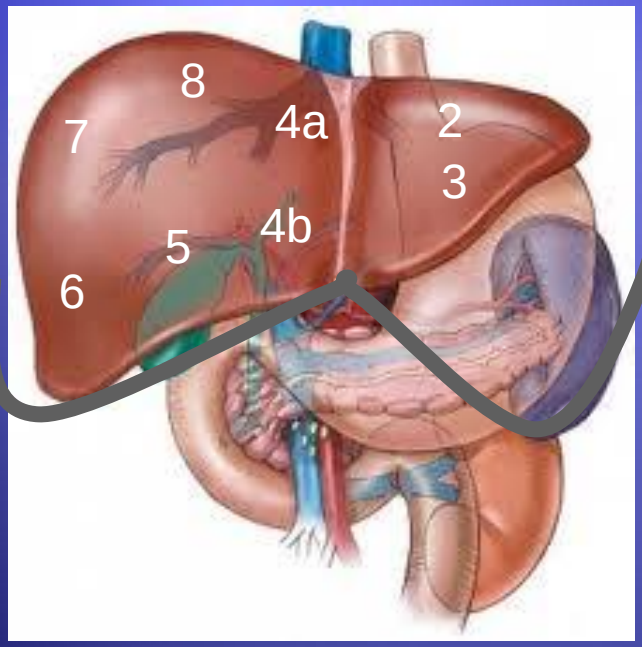

Foie D Ao G

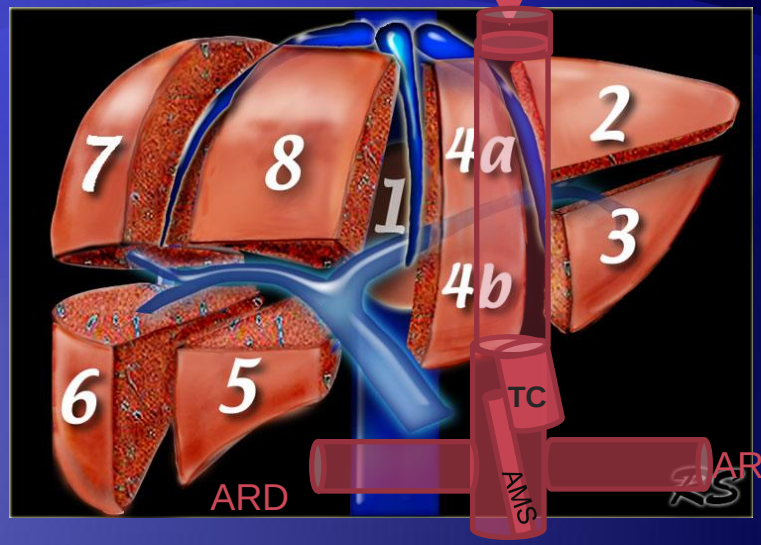

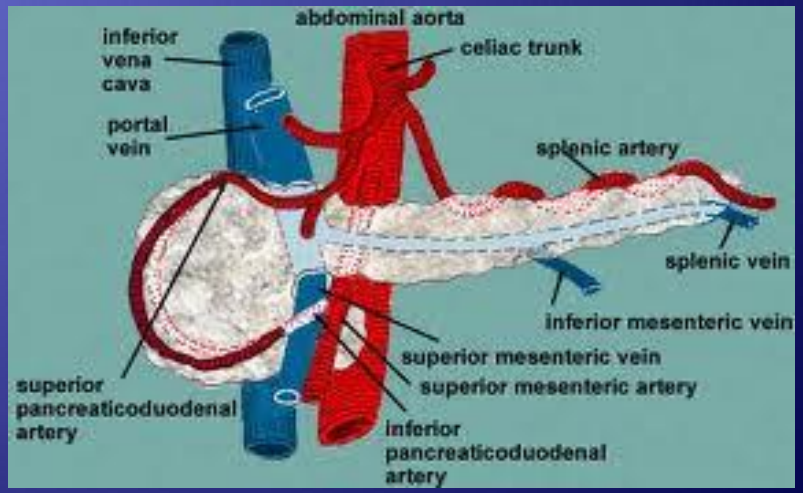

Le foie

- échostructure homogène
- bords lisses, contours réguliers
- aussi échogène (légèrement hyper) vs le cortex rénal

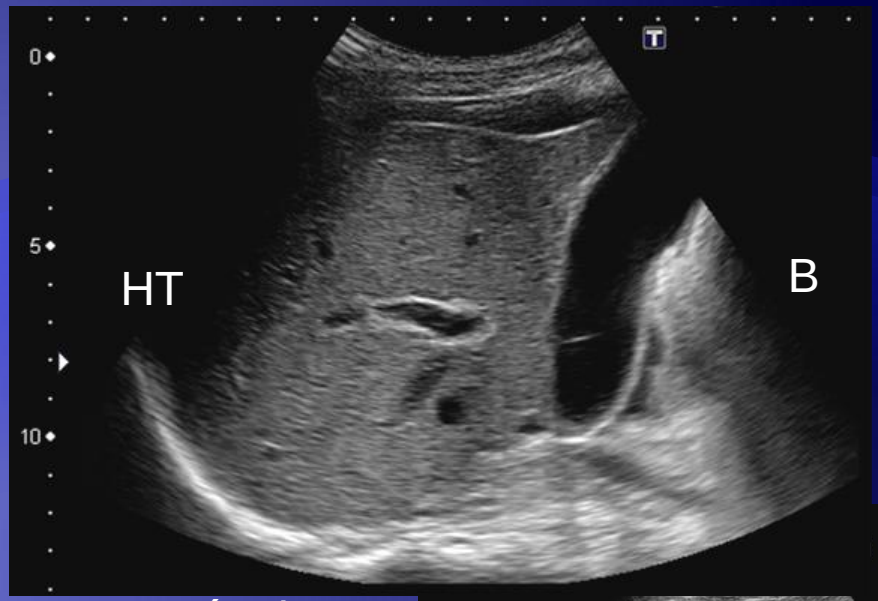

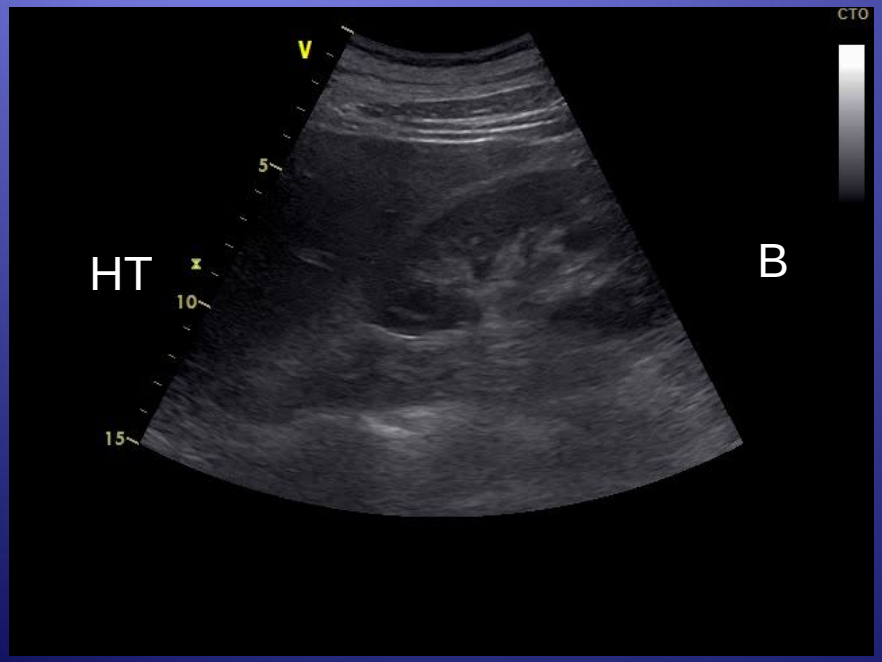

Les vx du foie en mode B

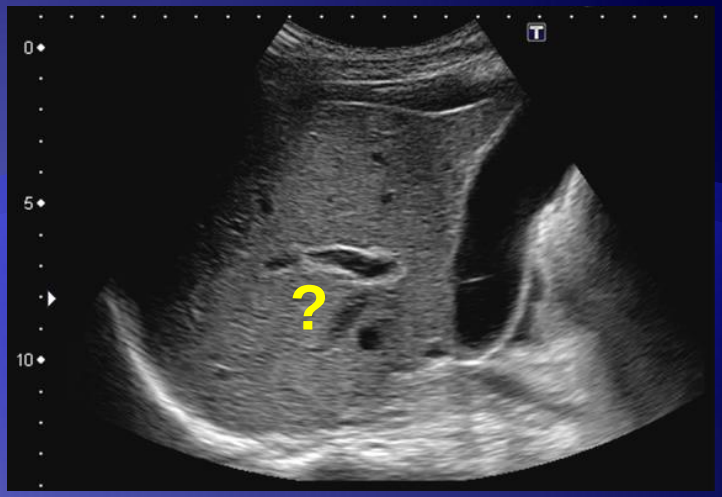

- VSH veines sus hépatiques
- Artères hépatiques
- système Porte
- Réseau biliaire

Les vx du foie en mode B

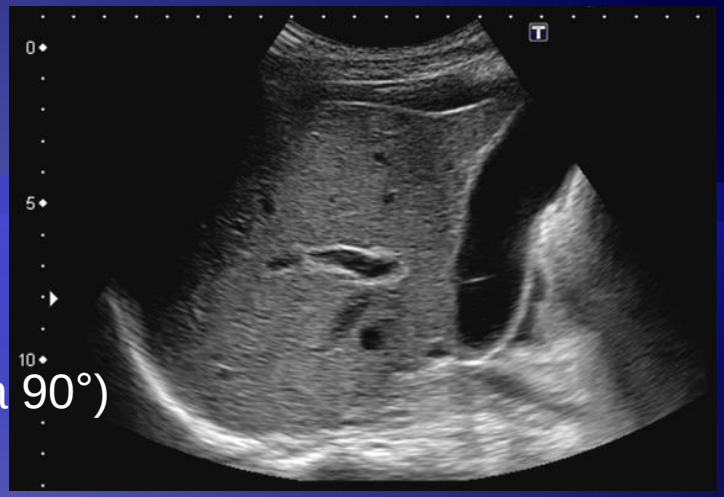

en coupe longitudinale >> axiale :

Vaisseaux sus hépatiques = pas de paroi (sauf à 90°)
Vaisseaux porte = paroi hyperéchogène

Artères hépatiques : paroi hyperéchogène
Mais diamètre 1-2 mm donc difficile à voir en mode B

Voies biliaires intrahépatiques quasi invisibles
Voies biliaires extrahépatiques
difficiles à voir en l'absence de dilatation (>10 mm),
en avant du tronc porte

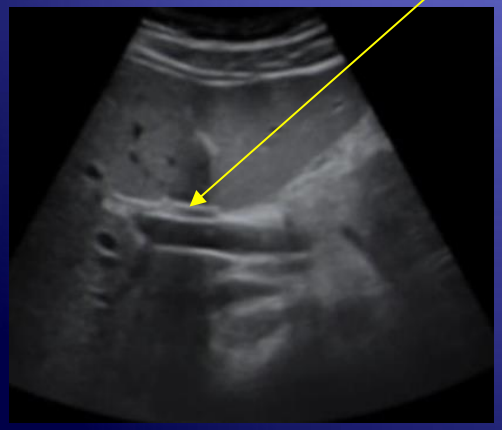

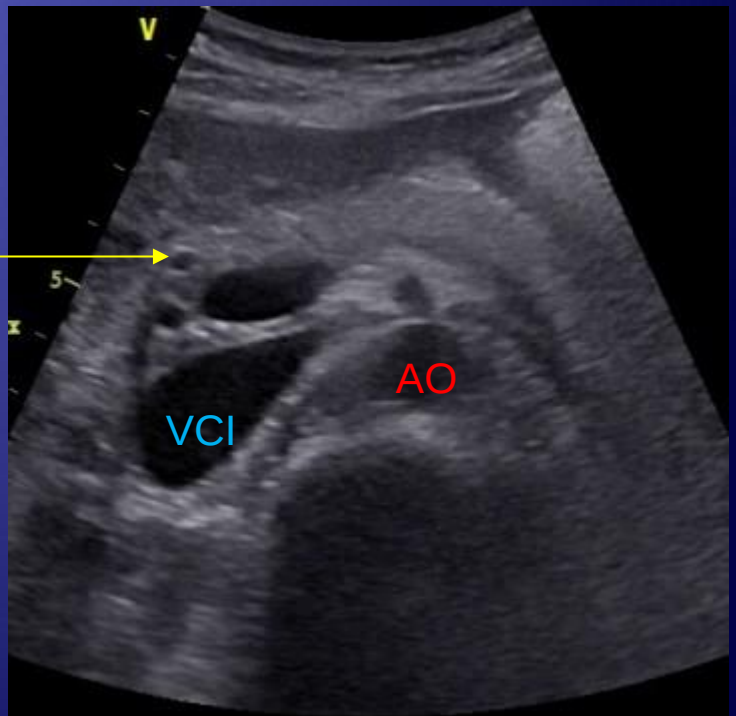

Les vx du foie en mode Doppler couleur ou pulsé

Intérêts :
Identifier les vaisseaux (vs voies biliaires +++)
Sens des flux +++ :
hépatofuge (VSH),
hépatopète (artère, veine porte)
Pas de flux : bile >>> Thrombose

Mesurer leurs débits ?

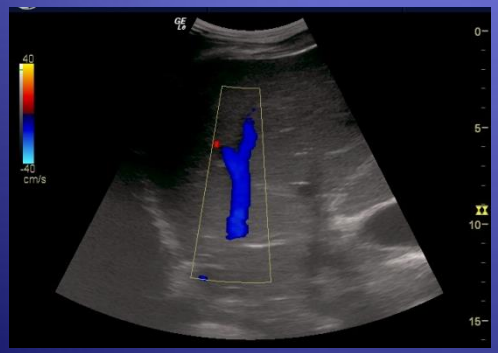

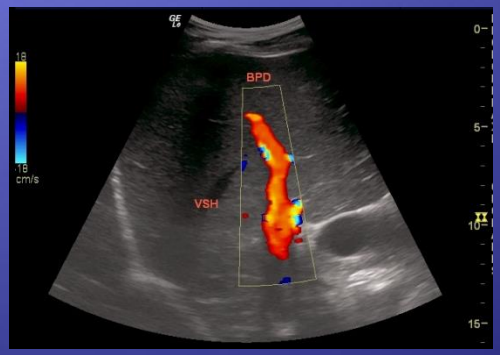

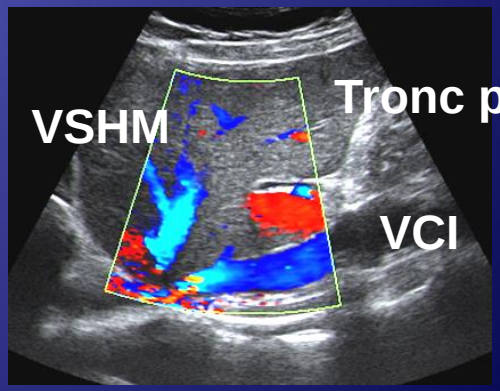

Région épigastrique

Hile hépatique et gros vaisseaux systémiques

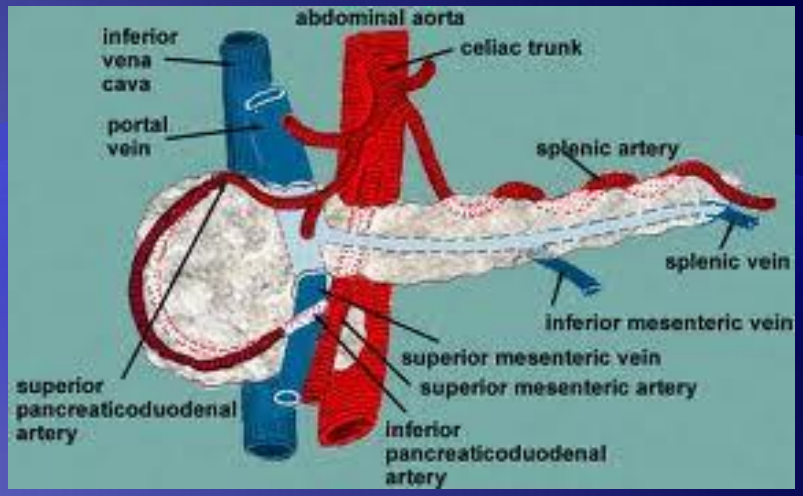

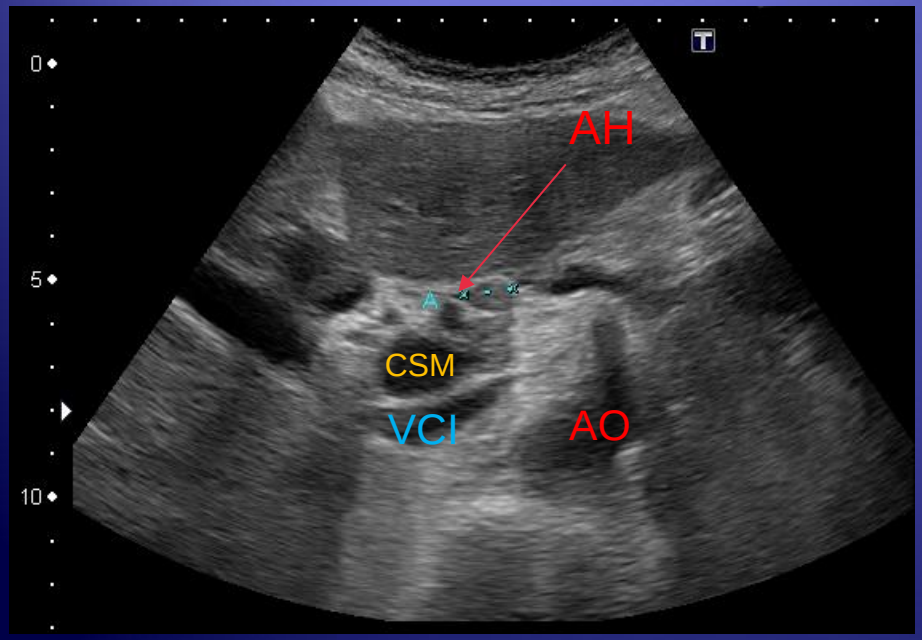

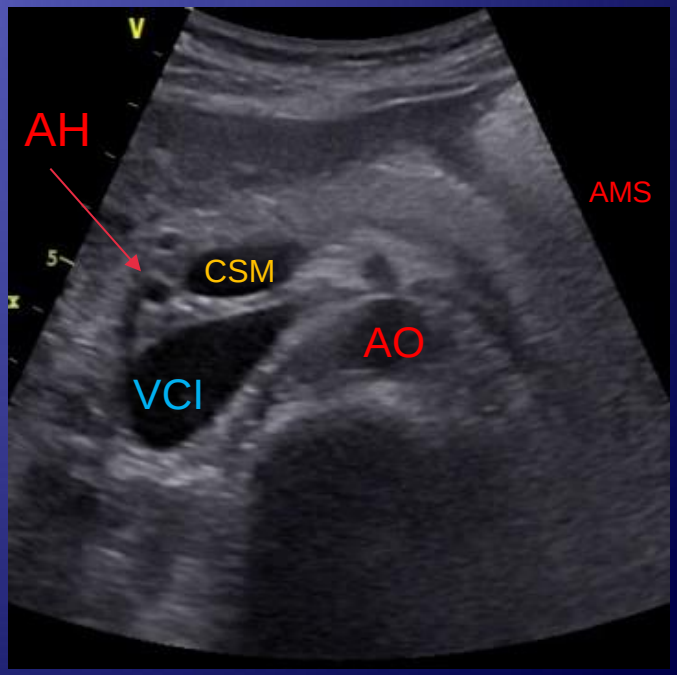

Repérage des vaisseaux :
1-Coupe épigastrique axiale

coupe récurrente sous costale

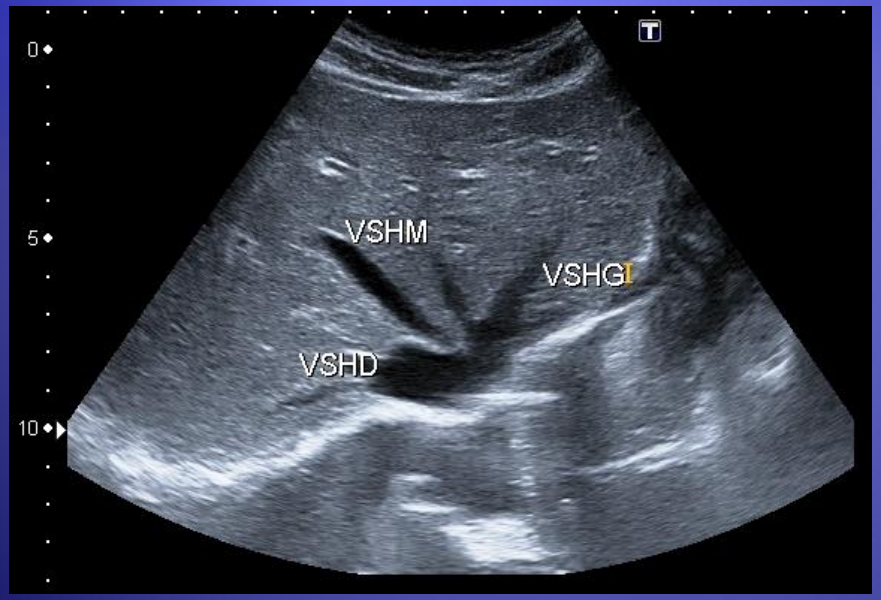

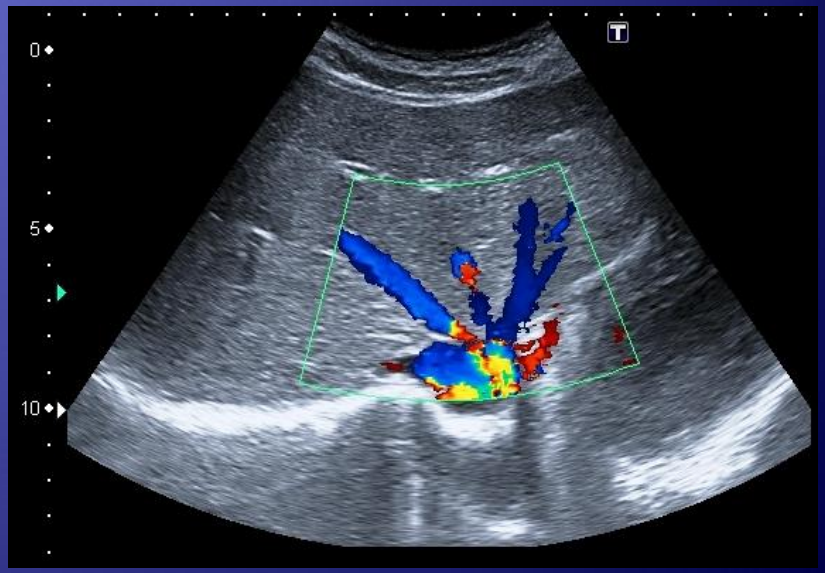

Repérage des vaisseaux :
1-Coupe épigastrique axiale vraie

Pancréas – CSM – VCI – AMS - Ao

TRANSVERSE = axiale

Coupe épigastrique axiale

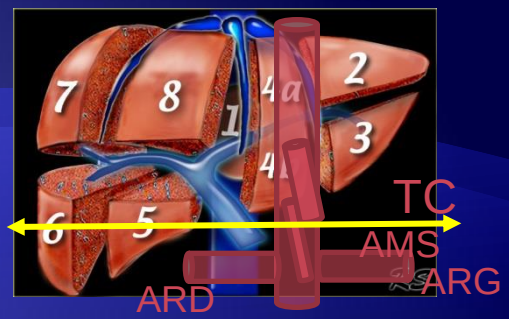

Pancréas – CSM – VCI – AMS - Ao

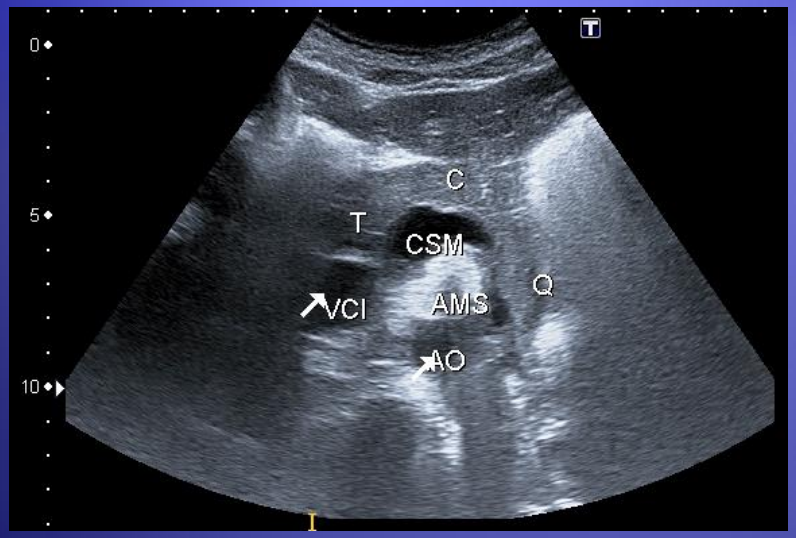

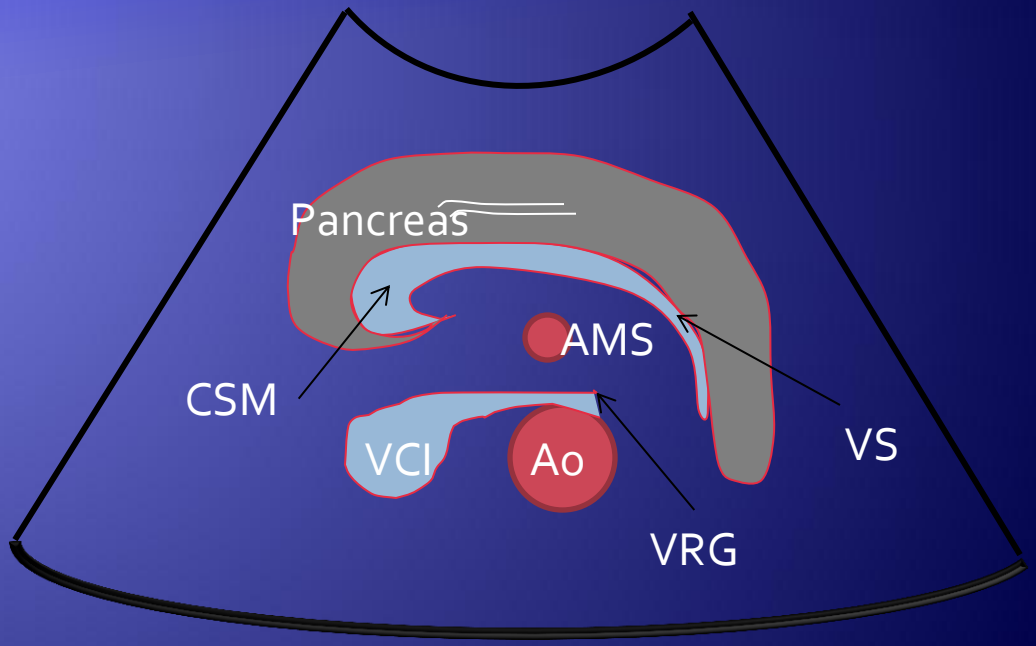

TRANSVERSE

2- Coupe épigastrique dans l'axe du tronc porte

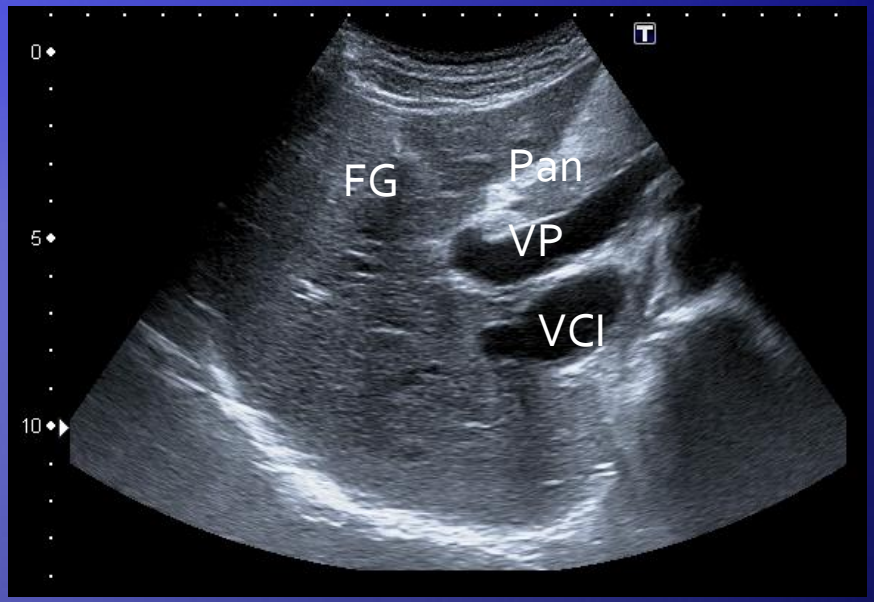

Rotation de 35 – 45° = parallèle au rebord costal droit
Veine porte : thrombus, sens du flux

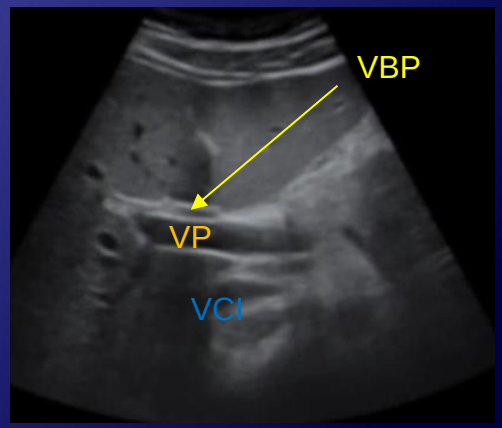

3- coupe sagittale de l'aorte



A = médiane

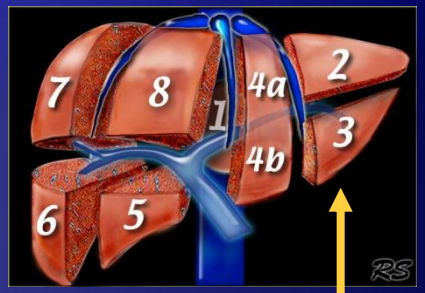

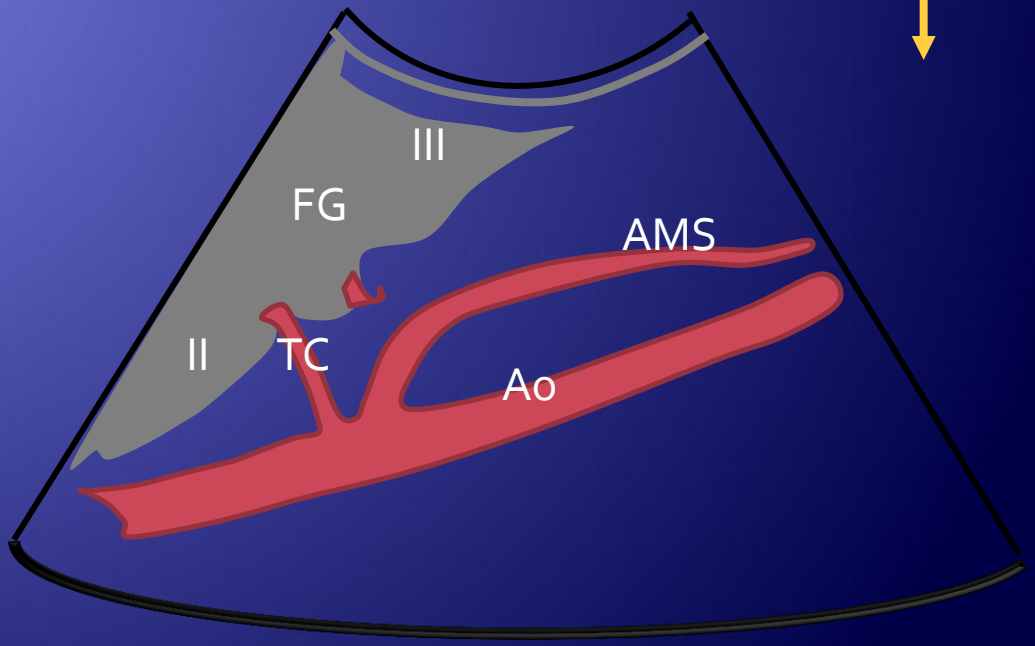

4- coupe sagittale sur VCI



B = para médiane interne

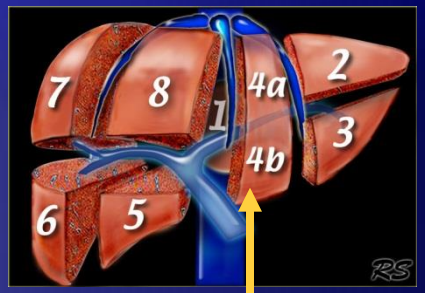

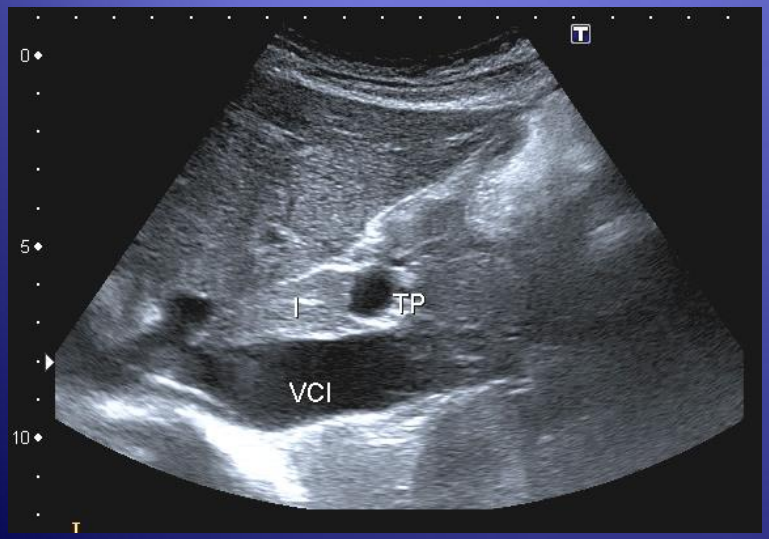

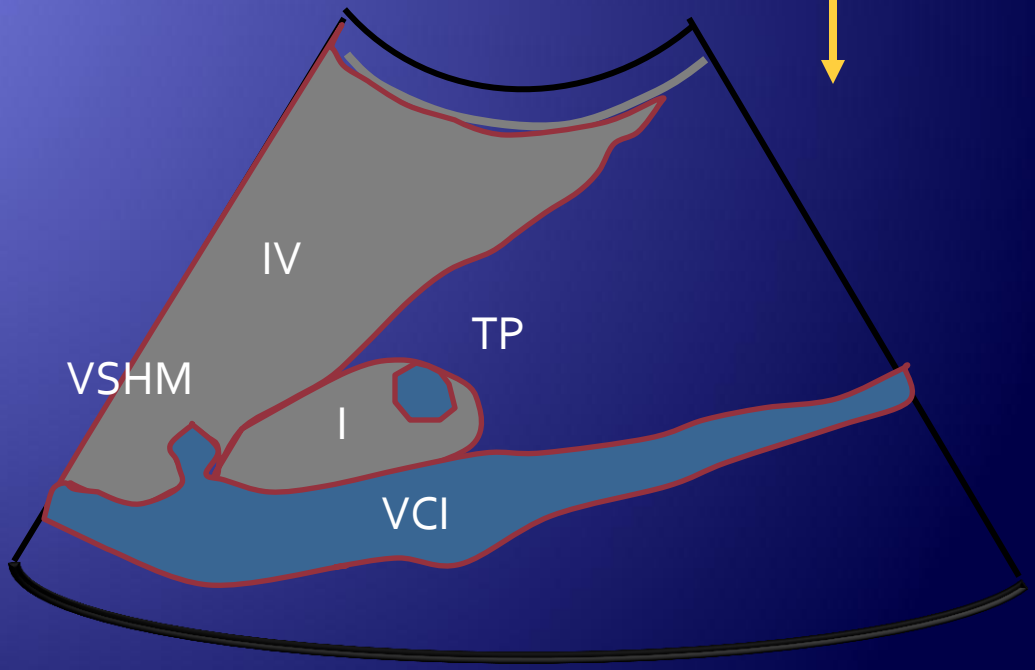

4- coupe sagittale sur VCI



B = para médiane interne

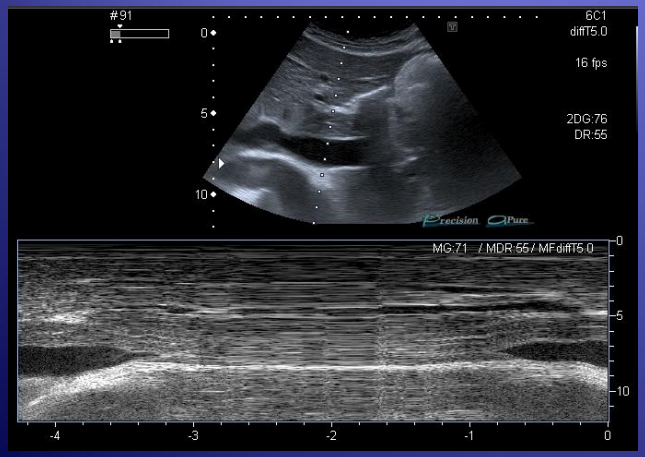

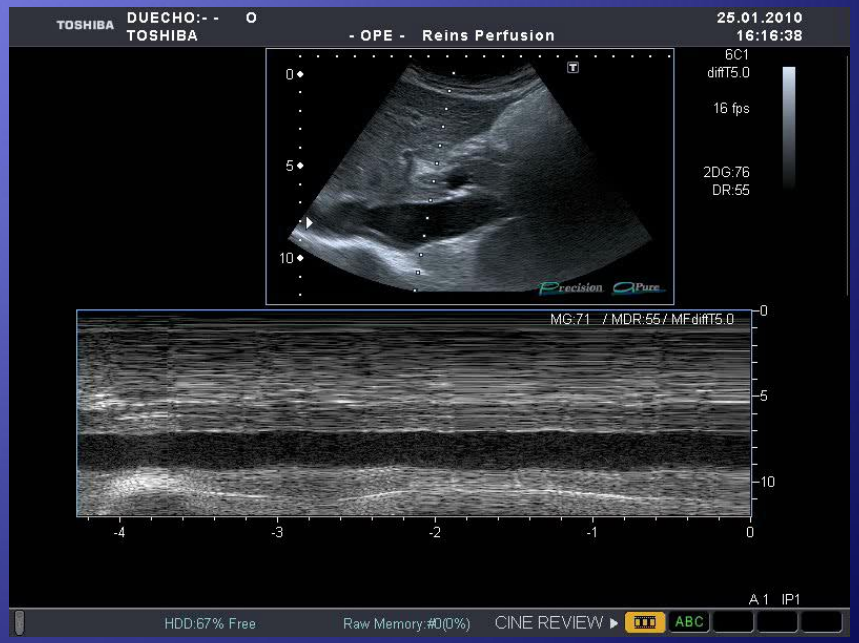

5- coupes sagittales de l'hypochondre D

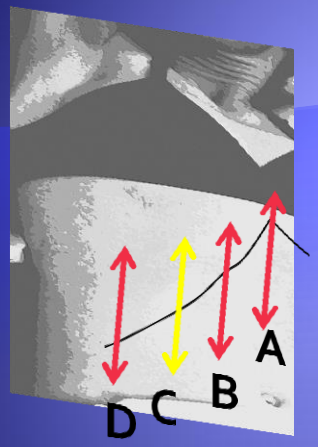

Vésicule biliaire

- transonore
- parfois sludge, lithiase (mobilité, localisation)
- peut être bilobée
- Paroi < 4 mm, non dédoublée
- indolore
- < 10 cm x 4 cm

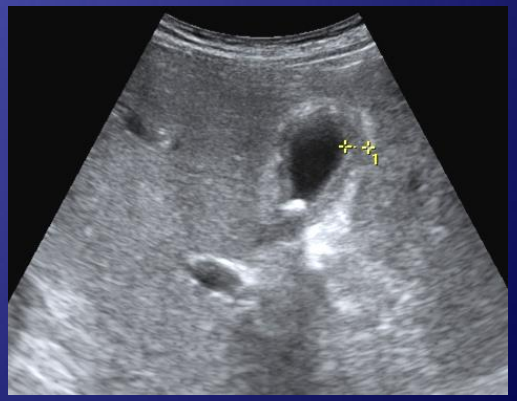

6- coupes sagittales de l'hypochondre D



D = para médiane externe
= loge de Morison

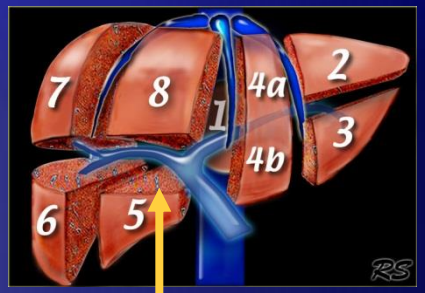

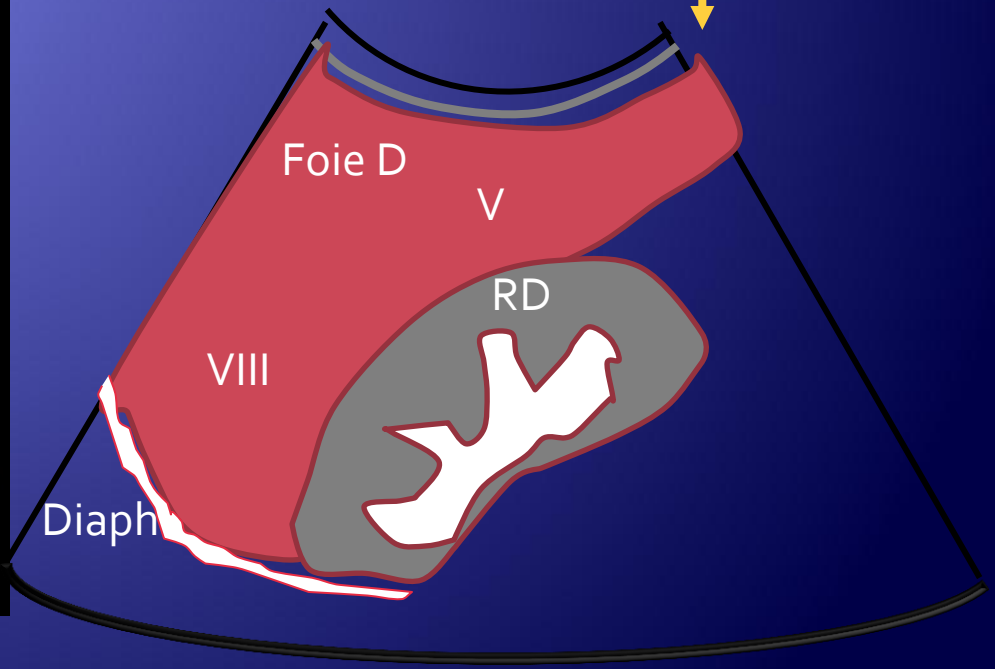

7-Hypochondre G = Rate + rein G

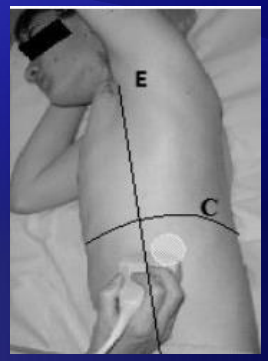

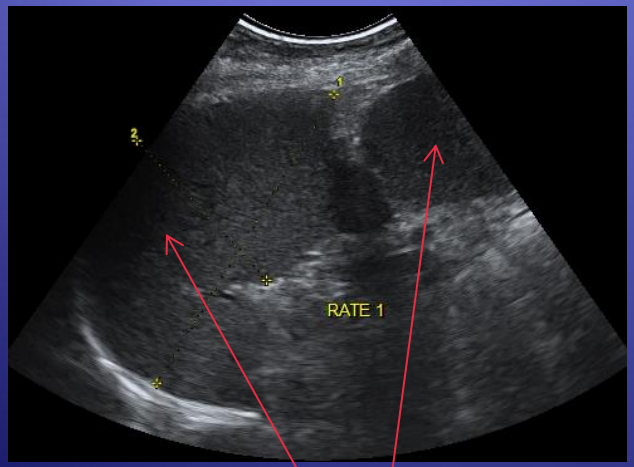

Deux rates

8-Les zones déclives

- Loge de Morison

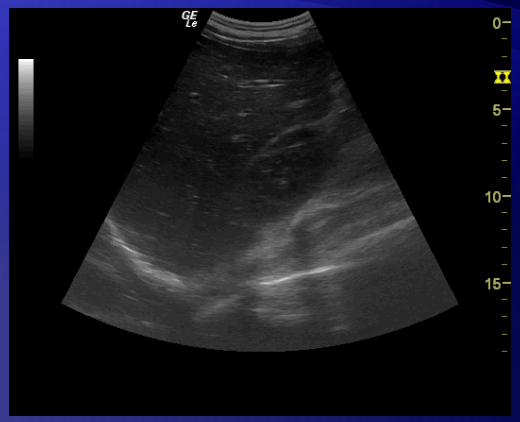

- Loge de Kohler entre rein G et rate

- Gouttières pariéto-coliques
- Espace sous phrénique
- Douglas

douglas

Entre vessie (ou uterus) et rectum

axiale

Douglas… et glandes seminales

F

longitudinale

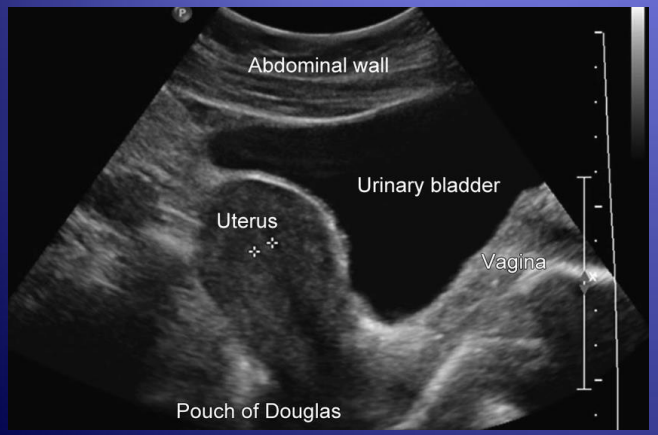

douglas

Sonde vésicale comme repère…

axiale

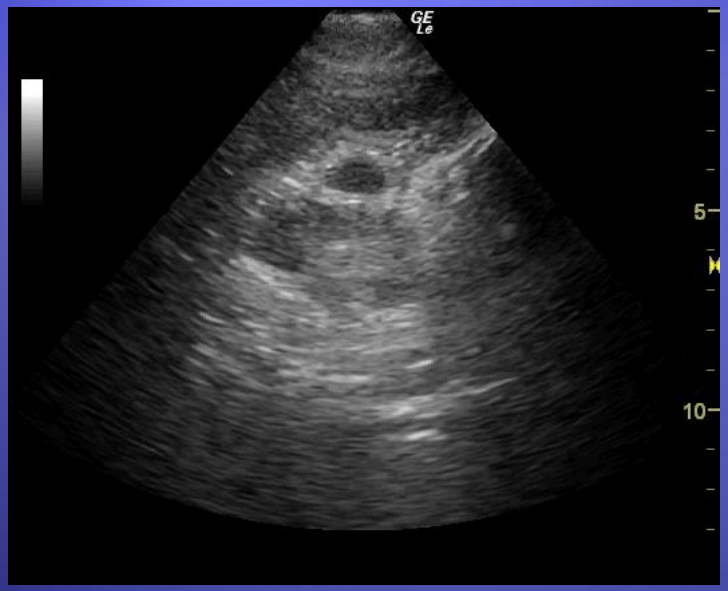

longitudinale

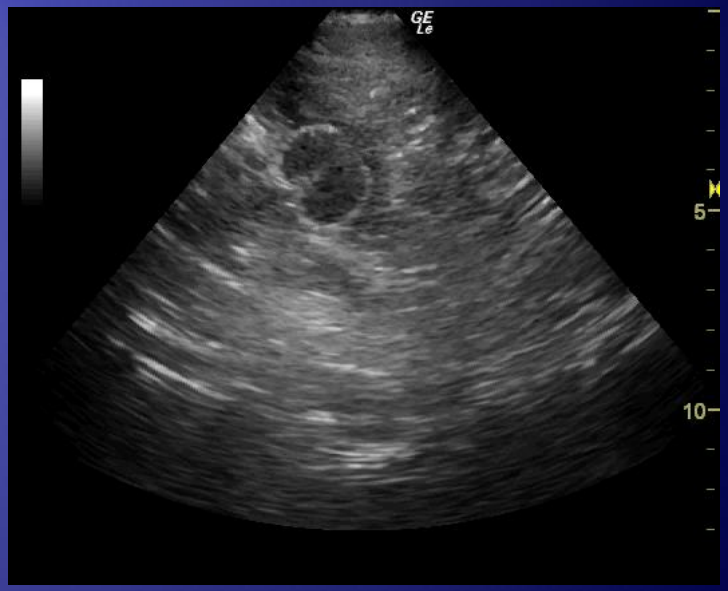

- douglas Entre vessie (ou uterus) et rectum

Péristaltisme digestif (echo plus sensible que l'auscultation)

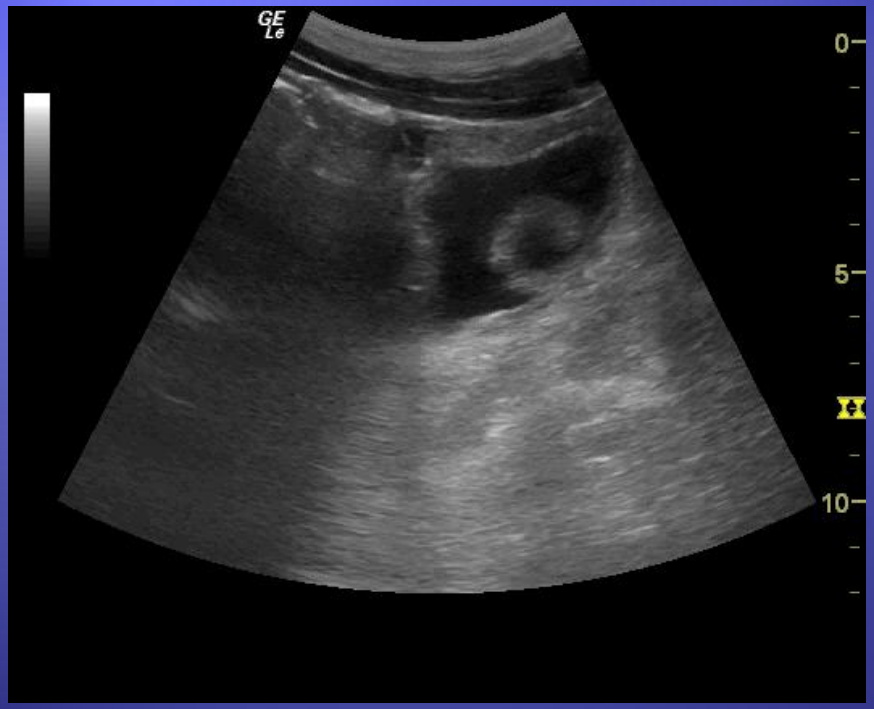

Echographie gastrique

vacuité gastrique

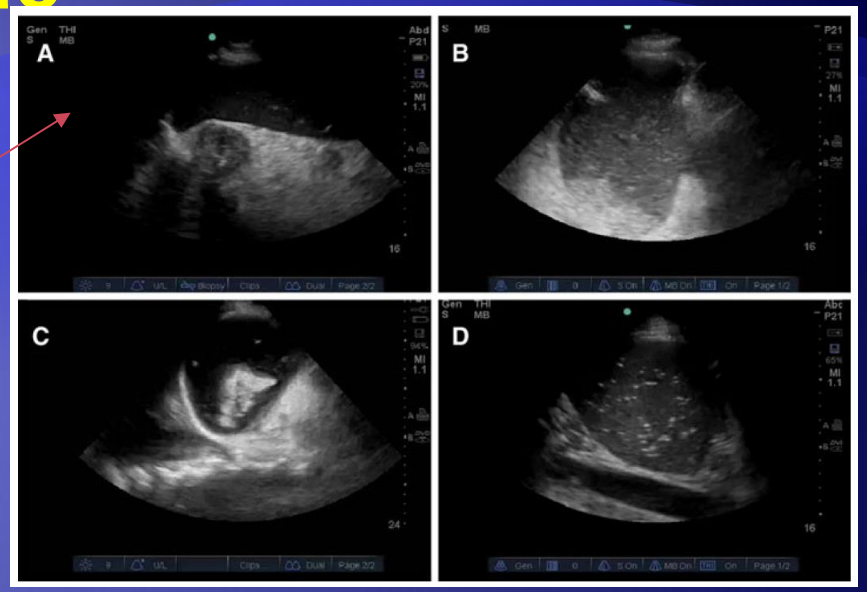

80 patients en détresse respi

80 patients :
5 : non vide mais pas de SG à poser
14 : indic à SG
13 SG : 200-1100 ml
1 crush : inhalation

Écho moy 2 min

Koenig *ICM* 2011

Echographie antrale

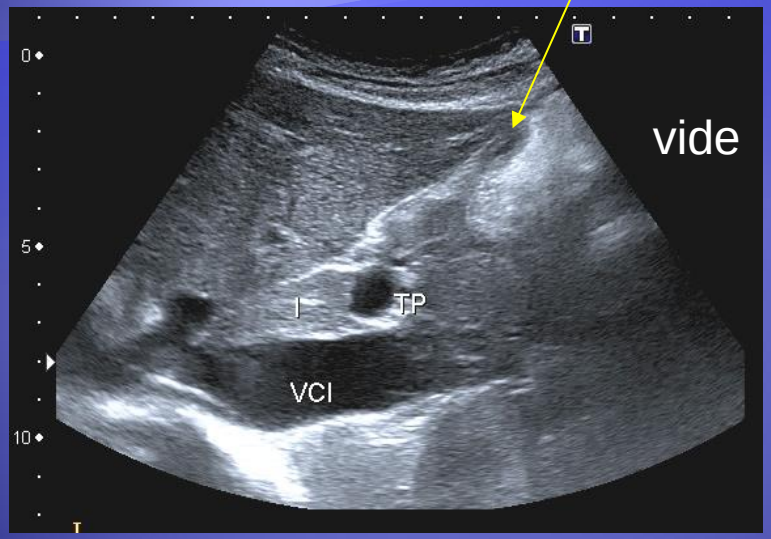

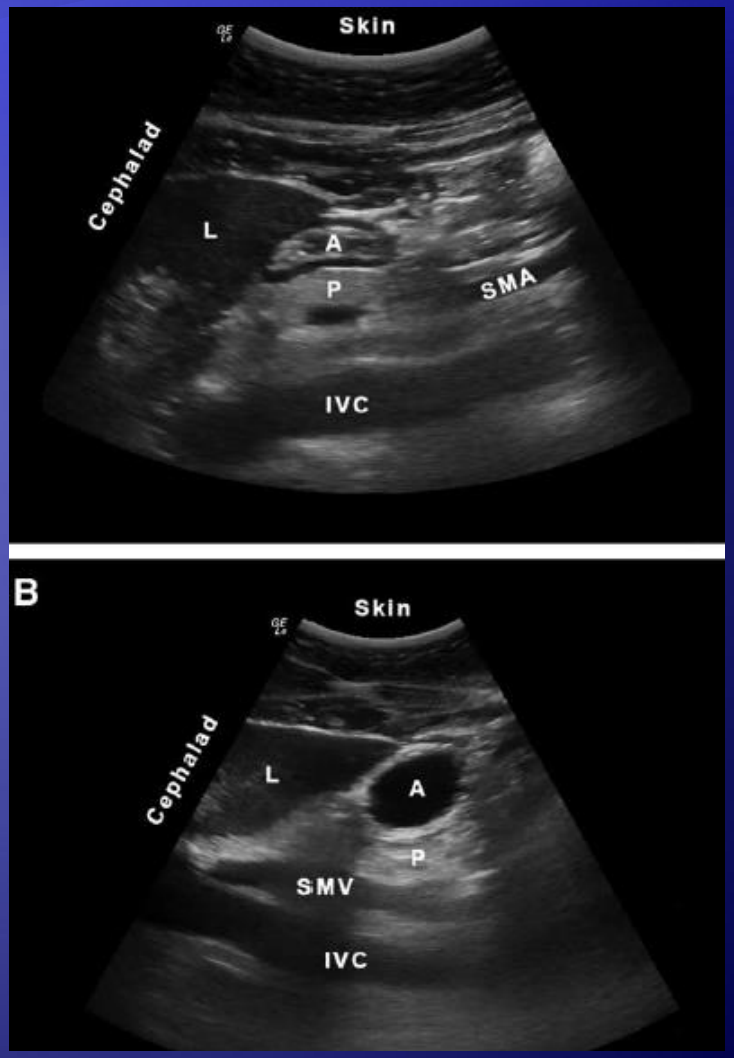

Reflète le volume gastrique +++
Intérêt avant intubation : estomac plein ou pas ?
Idéalement proclive voire léger decubitus D (éloigner l'air de l'antre + sensibilisation)
Aire = Longueur x largeur / 4 (cm2)
Seuil : 3,5 à 4 cm2 ?

Desgranges, Ann Rea 2020

coupe épigastrique

Sonde gastrique

Axiale = cône d'ombre

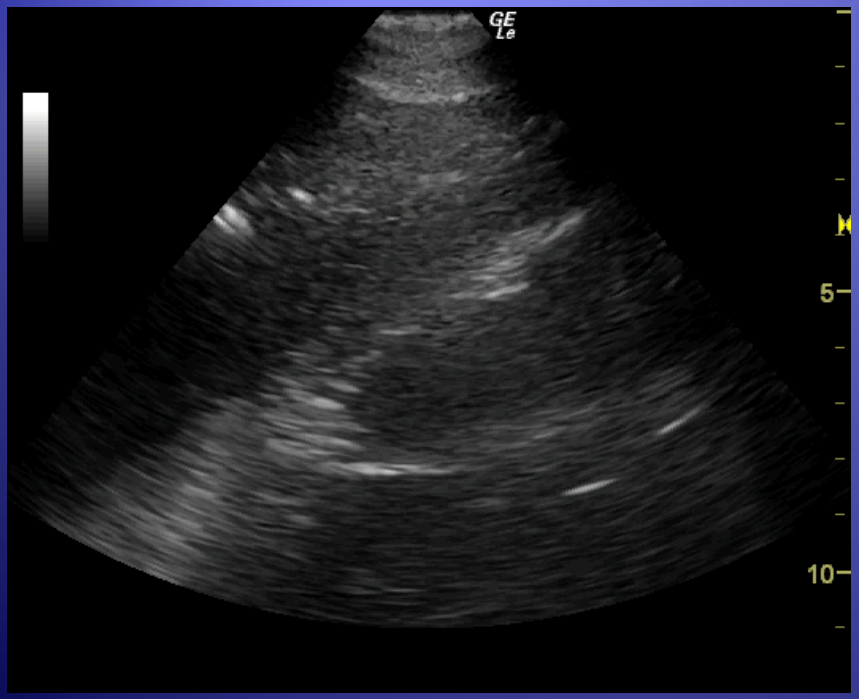

Longitudinale : rail

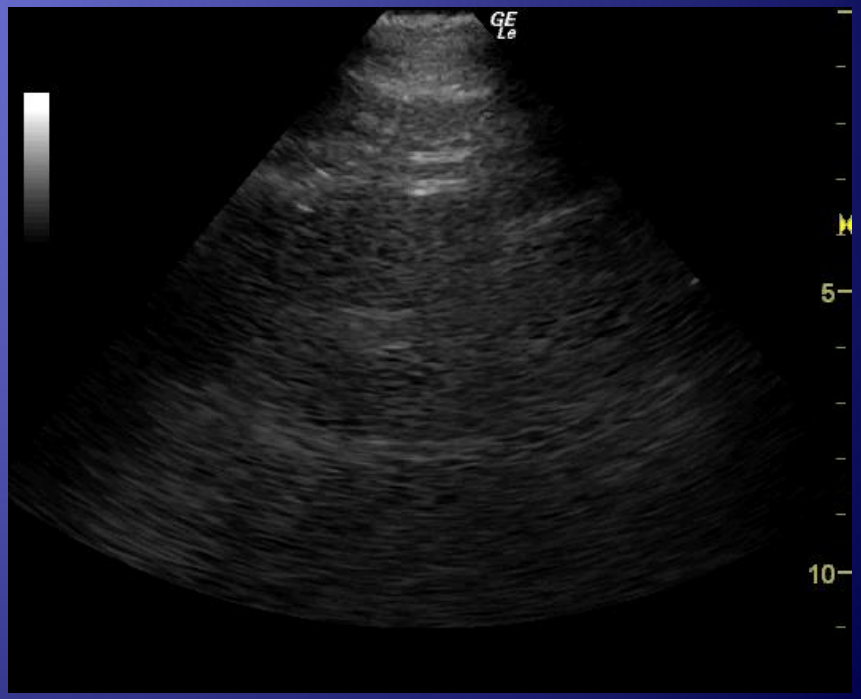

coupe épigastrique

Sonde gastrique

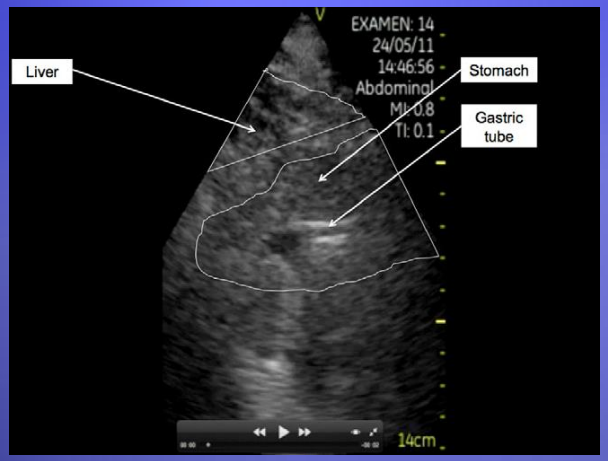

Patients intubés
Écho maxi 1 min

SE : 98%, Sp : 100%
VPP : 100%, VPN : 86%
18 et 16 Fr >> 14 Fr

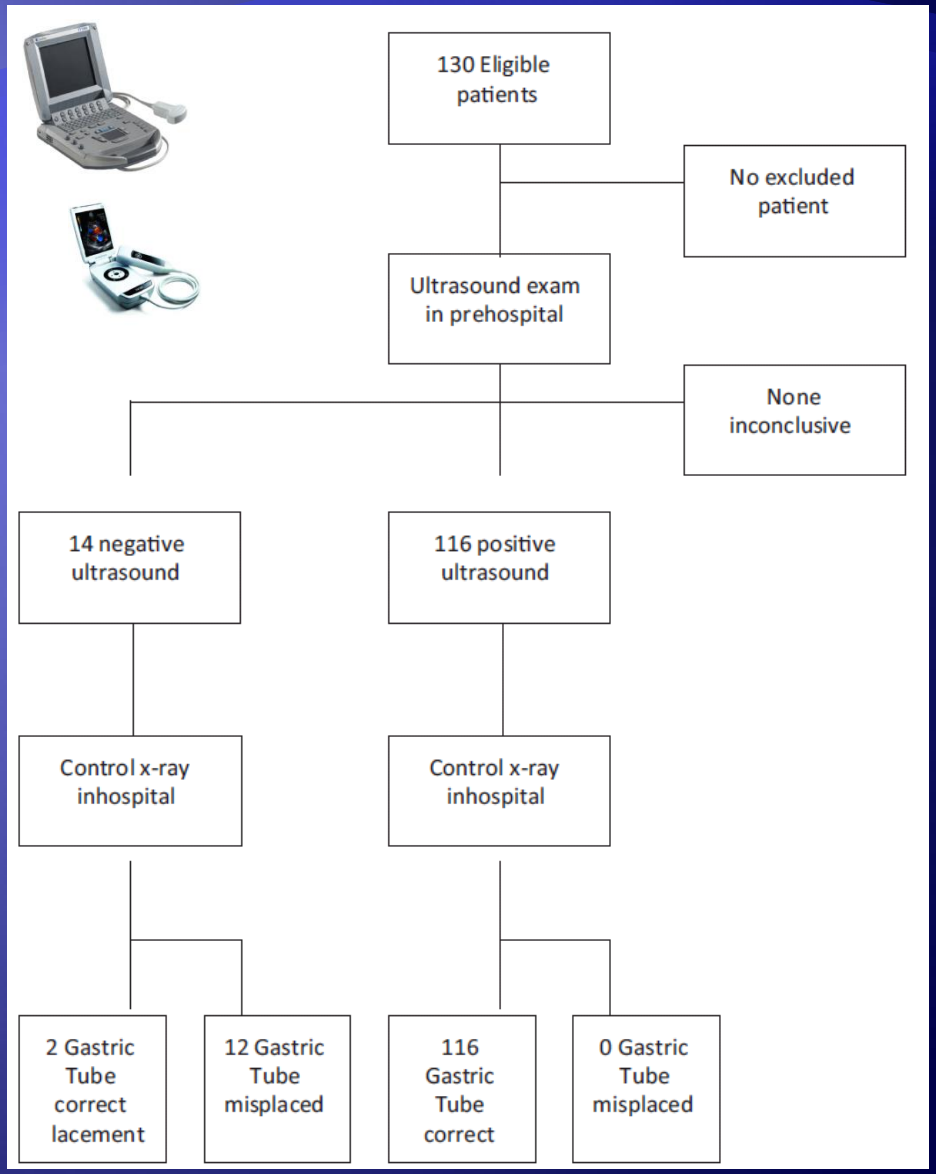

Chenaitia *Resuscitation* 2012

coupe épigastrique

Sonde gastrique

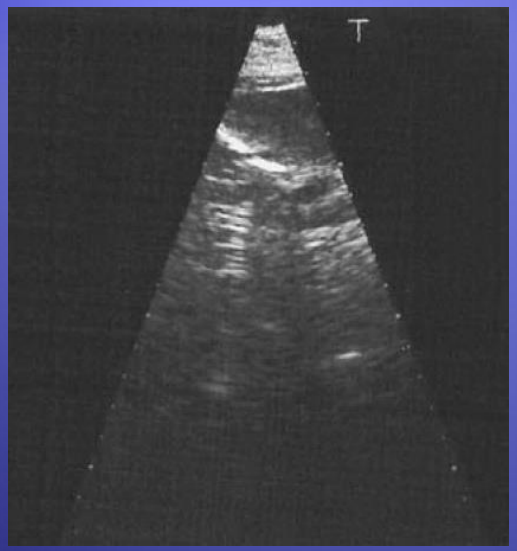

Sondes **de nutrition** 12 Fr (guide ôté)
79% patients intubés

33/35 patients : SG vue

Mais Écho moy 23 min (11-53min)…
vs RP 180 min (113-240)

Vigneau *ICM* 2005

Conclusion

- « pas de question, pas de réponse … »
- Examen débrouillage : réponse oui / non / nsp
Si NSP = radiologue
- Doppler couleur utile pour repérer les structures
- Compte rendu : différencier aspect écho / interprétation